



Childhood Masturbation: A Case Report and Literature Review for Treatment

*Ade Febrina Lestari^{1,2}, Meineni Sitaresmi^{2,3}, and Firda Ridhayani⁴

¹Child Health Department of Medical, Nursing and Community Health Universitas Gadjah Mada, Indonesia

²Child Health Department, Academic Hospital of Universitas Gadjah Mada, Yogyakarta, Indonesia

³Child Health Department, Sardjito General Hospital, Yogyakarta, Indonesia

⁴Master of Clinical Pharmacy, Faculty of Pharmacy, Universitas Gadjah Mada, Indonesia

*Corresponding author: adefebrina@ugm.ac.id

Submitted: January 2023

Reviewed: February 2023

Publish: March 2023

Abstract

Background: Masturbation is normal sexual behavior. However, masturbation in childhood is rarely discussed in the research. Childhood masturbation or gratification disorder, is characterized by self-stimulation of genitalia in prepubescent children. However, childhood masturbation often stops if the child is distracted, and spontaneous recovery within two years in most cases. Generally, no drug therapy is required for childhood masturbation unless it is very frequent or excessive and it affects the daily functionality of the child. Regarding the treatment of childhood masturbation, we highlight the fact that evidence-based therapy for childhood masturbation is lacking due to unclear standard guidelines on it. We need a path of therapy that can help doctors in the management of childhood masturbation.

Case: Here we reported two cases of excessive childhood masturbation from a 3-year-old and a 10-month-old female patient who were brought by their mother to the outpatient clinic pediatric, Academic Hospital, Universitas Gadjah Mada, Indonesia, with a complaint of stretching by flexing the legs and rubbing on her genital part. Risperidone as one of the drug therapies for this case and present a good outcome. Additionally, this article also provides literature reviews on childhood masturbation treatment that may guide clinicians in its evaluation and management. **Conclusion:** We conclude that behavioral treatment is the common strategy for childhood masturbation. The treatment, as well as behavioral and drug therapeutic strategies, should be considered to achieve an effective outcome.

Keywords: *Childhood masturbation, excessive childhood masturbation, treatment, risperidone, behavioral*

1. Introduction

Childhood masturbation (CM), also known as gratification disorder, is characterized by prepubescent children's self-stimulation of genitalia. Actually, masturbation is a normal sexual behavior seen in around 90% to 94% of men and 50% to 60% of women throughout their lives. However, masturbation in childhood is rarely discussed in the research (1-4). It characteristically starts at 2 months of age with a peak of incidence at 4 years and decrease after 5 years. There is spontaneous recovery within two years in most cases (4). Childhood masturbation is characterized by the child's rhythmic stimulation of his/her genital areas, generally with an object and accompanied by sweating, flushing, and tachypnoea. presented as unusual postures and movements, and could be misdiagnosed as seizure disorders, movement disorders, abdominal pains, or other neurologic or medical disorders (1-3,5-7). According to some research, the frequency of CM varies from 1 per week to 12 per day, and the duration varies from 30 seconds to 2 hours, and it is found to be 3-7 times more common in girls than in boys in the age range of 2-12 years (1,2,7). However, CM often stops if the child is distracted (8). In clinical practice, CM is sometimes confronted with parents who are worried about the masturbatory activity of their children and seek advice.

In Indonesian values, influenced by religion and culture, consider masturbation is perceived as a sinful activity. This negative perception causes children to experience less favorable treatment, such as scolding, lecturing and punishment. However, we still need a therapeutic pathway that can assist doctors in managing these cases. Here we aim to report a case of CM from Indonesia and literature review for therapy, so that clinicians can consider it as a reference.

2. Case

We describe the cases of a 3-year-old and a 10-month-old female patient who were brought by their mother to the outpatient clinic pediatric, Academic Hospital, Universitas Gadjah Mada, Indonesia, with a complaint of stretching by flexing the legs and rubbing on her genital part, which had already started one year ago and had progressively more frequent, almost every day

rubbing on her genital with her hand, with part of a bicycle, corner of a bed, and other objects.

It occurs more than 2-3 times per day, with signs of flushed face, sweating, and increased frequency of her respiration, and it can stop when her mother distracts her. There was no history of sexual abuse, no altered emotions, no fever, or enuresis, and no history of urinary tract infection. There was no internet access or inappropriate exposure to the child. The physical examination shows normal, as does the neurological examination. There was no sign of laceration or infection on the genital part. The urine test was normal. Electroencephalography (EEG) was not obtained because there was no sign of epilepsy or history of seizure. She had reached developmental stages appropriate for her age based on the Denver II test.

The assessment was given by the pediatrician as excessive childhood masturbation, and the child was given risperidone with a dose of 0.01 mg/kg of body weight per day because of the excessive masturbation behaviors. Follow up was given after 4 weeks. Risperidone was preferred because of its availability and acceptable price for patients. After follow-up for about 4 weeks, there was a significant decrease in complaints. In all, there was only one masturbation observed in the first four weeks, and no side effects were reported. for another 4 weeks. On the last visit, there was no complaint at all. Risperidone was tapered off and stopped.

3. Discussion

Children were reported to masturbate when they felt bored and agitated. Traumatic reasons such as the history of a new sibling, staying away from parents, or abuse may start masturbation by leading to a decrease in the relationship that the child develops with its environment and the turning of the child to his/her own body (7). Another factor facilitating masturbation is local irritation caused by infection or dermatological diseases of the genital area (9). Children with a severe lack of external stimulation, or some orphanage children, were prone to masturbation (3). Maternal education, parental attitudes toward sexuality and family sexuality, stress and violence in the family are associated factors in sexual behavior (3). Common features of CM in

infants are: 1. episodes of stereotyped posturing of the lower extremities and/or mechanical pressure on the perineum or suprapubic area; 2. associated intermittent (quiet) grunting, irregular breathing, facial flushing, and diaphoresis; 3. variable duration of the episode (lasting from a few seconds to several hours) and variable frequencies of episodes (ranging from once in a while to almost continuously); 4. no alteration of consciousness; 5. cessation with distraction; and 6. the episodes cannot be explained by abnormalities on physical and other diagnostic (technical, laboratory) examinations (9,10).

The diagnosis of CM, thus, depends upon awareness, careful interrogation, and video recording. One of the most important features of CM is that the child stops if he/she is distracted (11). It is also important to differentiate masturbation from frequently confused neurological situations. In particular, epilepsy and non-epileptic paroxysmal events must be carefully eliminated. In the literature, it is known that many patients have received antiepileptic treatments with neurological diagnoses (12,13). Autism Spectrum Disorder and Intellectual Disability are frequently seen conditions in cases of excessive masturbation (14). It must also be considered in the differential diagnosis whether or not excessive childhood masturbation is a sign of obsessive-compulsive disorder. Comorbidities of psychiatric disorders in children, such as attention deficit hyperactivity disorder (ADHD), anxiety, communication disorder, learning disabilities (LD), tics, obsessive compulsive disorder (OCD), mood disorder, and intellectual disabilities (ID), are more common in CM (7,14). Excessive childhood masturbation is not included in the Diagnostic and Statistical Manual of Mental Disorders (DSM) as a psychiatric disorder but is classified as "other specified behavioral and emotional disorders with an onset usually occurring in childhood and adolescence" in the international Classification of Diseases (ICD-10) (15,16).

There is very limited literature for drug therapy for childhood masturbation. Maybe because there are different opinions about the normality or abnormality of masturbation. Masturbation occurs throughout the lifespan and

most commonly occurs at 4 years of age and then again during adolescence (3). However, it is necessary to define natural sexual behavior according to society's norms, religion, culture, and family background; otherwise, normal sexual behavior cannot be distinguished (14,17-19). When masturbation behavior is conducted in a private setting and is not excessive in nature, it is considered to be a normal part of child development. This behavior, however, may be considered inappropriate when it occurs for a sustained period of time and/or in public spaces and thus may warrant the need for intervention (14). Drug therapy was reported for cases with very frequent masturbation, affects the daily functionality, distorting performance in a school environment and preventing school attendance (6).

There are review literature which investigated assessment and treatment approaches for childhood masturbation among children with typical development and developmental disabilities (14,17). For children with typical development, the guideline for CM is suggested that the process should begin with an assessment that includes questions about the child's development, including affect, behavior, and sleep; questions about potential genitourinary or other medical problems; and consideration of cultural, familial, historical, relationship, and environmental variables. The signs of sexual abuse and/or skin irritation also need to be eliminated. When the assessment identifies that there are no additional confounding factors, it is recommended that treatment should focus on parental education and support. Educational processes should aim to alter parent perceptions of CM so that it is not viewed as pathology but, rather, a typical part of child development. It is further recommended that occurrences of CM should either be ignored or redirected and not punished due to the potential reinforcement that can come from responding to this behavior. Developmentally appropriate sex education should be provided to children in order to help them to understand what socially appropriate sexual behavior is and what it is not (14,17).

In one study on children suffering from autism, who were simultaneously experiencing masturbation, the efficacy of Mirtazapine on decreasing this behavior was investigated, and the results revealed that this drug effectively reduced the frequency of masturbation after two weeks of treatment (20). Risperidone with behavior therapy was reported to be more effective than behavior therapy alone in four weeks of treatment in children aged 3-7 years old (6). The addition of risperidone to the behavioral treatment, which was only effective at younger ages in the control group, was effective at all ages (6). The effectiveness of the behavioral treatment, which consisted of distracting the child during masturbation, would probably decrease with the aging and concentration of the child's attention and concentration on his/her atmosphere, whereas using drug therapy with the behavioral treatment can be considerably influential at all ages (6).

In the case of the childhood autistic spectrum, inappropriate sexual behaviors, specifically excessive masturbation are frequently observed. The differential diagnosis must also take into account whether or not excessive childhood masturbation is a sign of obsessive-compulsive disorder (21). Several studies reported the drug of choice for excessive CM in children and adolescents with autism spectrum including mirtazapine and escitalopram. Both of the drug had the effect of diminishing the frequency of excessive CM (21–23). Aripiprazole has also been reported as a drug therapy for excessive CM (21). Aripiprazole, with less sedative effect than risperidone, has the known effect of reducing impulsive behaviors. It has been reported in the literature that aripiprazole has the ability to reduce impulsive behaviors, especially in autism (21).

Table 1. Summary of literature investigating case and management for childhood masturbation

Author	Participant and Case	Management	Management Result
Yang, et al. (10).	Reported the 12 girls were referred to a pediatric movement disorders clinic between 1997 and 2002. All of the children were determined to have dystonia like posturing during masturbation. Most of patient have specific characteristic features such as facial flushing, facial grimacing, staring on head/face, and twisting arm posture.	Ten of the 12 had obtained diagnostic testing including MRI, EEG, or metabolic testing. The study suggests to redirection the children in other activities to bring up their interest and educate the children about appropriate sexual behavior.	The suggestion to redirect children to other activities has positive results. Parents successfully get children's attention and stop their rhythmic activity.
Omranifard, et al. (6)	A randomized clinical controlled trial study from children who have been admitted to Child and Adolescence Psychiatric Clinic of Isfahan University of Medical Sciences.	Types of management classified into two group: 1. Group 1: Medicated simultaneously by behavioral therapy and 0.25 – 1.0 mg of Risperidone once daily in four weeks of treatment. 2. Group 2: Only treated with behavioral treatments	The study result showed a more reduction in masturbation frequency when the patient received both behavioral therapy and risperidone medication compared with single behavioral therapy.
Albertini, et	A child (5-year-old boy) with a	The patient received a	The treatment

al. (24).	severe autistic syndrome worsened by hypersexual behavior consisting of compulsive masturbatory activity.	selective serotonin reuptake inhibitor drug, 5 mg /day dose of mirtazapine for 6 months of treatment.	successfully improved the clinical patient conditions, including disappear of hypersexual behavior, communication improvement, and reduce aggressiveness that influences better emotional response.
Kul, et al. (21)	A seven year and two-month-old female patient brought by her mother to the clinic with a complaint of stretching by flexing the legs and rubbing on objects. She has repeated masturbation behavior 15-20 times in a day. The examination of neurological and EEG result is normal.	The patient received 1 mg/day of risperidone as initial therapy for ten days of treatment and 1.5 mg/day of risperidone as maintenance therapy after two weeks of follow up.	The initial treatment using 1 mg/day risperidone did not show a positive outcome, without complaint reduction. A higher dose of risperidone, 1.5 mg/day, slightly decreases the masturbation behavior but influence excessive sleepiness and fatigue.

Based on the literature above, a management flow is made that can make it easier to choose therapy based on the presence or

absence of excessive CM, comorbidities, and the type of child development.

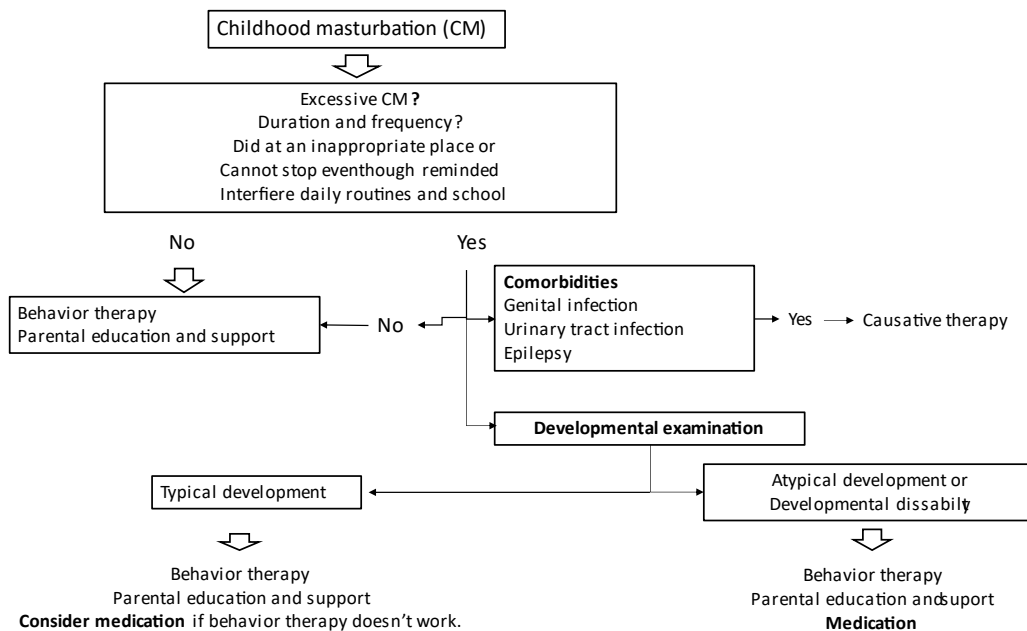


Figure 1. Treatment for childhood masturbation

4. Conclusion

Treatment for CM depends on the presence of excessive CM and patient comorbid, and the type of child development. Children with CM will mostly disappear without medication with age.

Medication should be considered if behavioral therapy and parental education and support do not improve the symptoms in a typical development child or no therapist instead. If there are co-morbidities such as urinary tract

infection, infection, or inflammation of the genital area, it must be treated according to the cause.

5. Abbreviation

ADHD: Attention Deficit Hyperactivity Disorder

CM: Childhood Masturbation

DSM: Diagnostic and Statistical Manual of Mental Disorders

EEG: Electroencephalography

ICD: International Classification of Disease

ID: Intellectual Disabilities

LD: Learning Disabilities

OCD: Obsessive Compulsive Disorder

6. Acknowledgements

This work was facilitated by the Academic Hospital Universitas Gadjah Mada.

7. Funding

No funding was received

8. Ethics approval and consent to participate

Consent to participate was performed to parent before manuscript submitted and available from corresponding author.

9. Competing interests

The authors declare that they have no competing interests.

References

- Doust ZK, Shariat M, Zabandan N, Tabrizi A, Tehrani F. Diagnostic Value of the Urine Mucus Test in Childhood Masturbation among Children below 12 Years of Age: A Cross-Sectional Study from Iran. *Iran J Med Sci*. 2016 Jul;41(4):283–7.
- Ajlouni HK, Daoud AS, Ajlouni SF, Ajlouni KM. Infantile and early childhood masturbation: Sex hormones and clinical profile. *Ann Saudi Med*. 2010;30(6):471–4.
- Leung AKC, Robson LM. Childhood Masturbation. *Clin Pediatr (Phila)*. 1993 Apr 1;32(4):238–41.
- Tashakori A, Safavi A, Neamatpour S. Lessons learned from the study of masturbation and its comorbidity with psychiatric disorders in children: The first analytic study. *Electron Physician*. 2017 Apr;9(4):4096–100.
- Nechay A, Ross L, Stephenson J, O'Regan M. Gratification disorder (“infantile masturbation”): a review. *Arch Dis Child*. 2004 Mar;89(3):225–6.
- Omranifard V. Risperidone as a treatment for childhood habitual behavior - PubMed. *J Res Pharm Pract*. 2013;2(1):29–33.
- Izadi-Mazidi M. Pathological Childhood Masturbation in Children Who Referred to a Child and Adolescent Psychiatric Clinic. *Journal of Comprehensive Pediatrics [Internet]*. 2020 [cited 2023 Jan 20];11(3). Available from: <https://www.semanticscholar.org/paper/Pathological-Childhood-Masturbation-in-Children-Who-Izadi-mazidi-Riahi/26a4f74d8b0dc0b31e70609f7ba092a316bdfcbe>
- Wilkinson B, John RM. Understanding Masturbation in the Pediatric Patient. *Journal of Pediatric Health Care*. 2018 Nov 1;32(6):639–43.
- Hansen JK, Balslev T. Hand activities in infantile masturbation: A video analysis of 13 cases. *European Journal of Paediatric Neurology*. 2009 Nov 1;13(6):508–10.
- Yang ML, Fullwood E, Goldstein J, Mink JW. Masturbation in Infancy and Early Childhood Presenting as a Movement Disorder: 12 Cases and a Review of the Literature. *Pediatrics*. 2005 Dec 1;116(6):1427–32.
- Casteels K. Video reveals self-stimulation in infancy. *Acta Paediatr*. 93:844–6.
- Fleisher DR, Morrison A. Masturbation mimicking abdominal pain or seizures in young girls. *The Journal of Pediatrics*. 1990 May 1;116(5):810–4.
- Mink JW, Neil JJ. Masturbation mimicking paroxysmal dystonia or dyskinesia in a young girl. *Movement Disorders*. 1995;10(4):518–20.
- McLay L, Carnett A, Tyler-Merrick G, van der Meer L. A Systematic Review of Interventions for Inappropriate Sexual Behavior of Children and Adolescents with Developmental Disabilities. *Rev J Autism Dev Disord*. 2015 Dec 1;2(4):357–73.
- The American Psychiatric Association's. *Diagnostic and statistical manual of mental disorders: DSM-5TM*, 5th ed. Arlington, VA, US: American Psychiatric Publishing, Inc.; 2013. xlv, 947 p. (Diagnostic and statistical manual of mental disorders: DSM-5TM, 5th ed).

16. World Health Organization. The ICD-10 Classification of Mental and Behavioural Disorders: Clinical descriptions and diagnostic guidelines [Internet]. 1992 [cited 2023 Jan 20]. Available from: <https://www.who.int/publications-detail-redirect/9241544228>
17. Mallants C, Casteels K. Practical approach to childhood masturbation—a review. *Eur J Pediatr*. 2008 Oct 1;167(10):1111–7.
18. Heiman ML, Leiblum S, Cohen Esquilin S, Melendez Pallitto L. A Comparative Survey of Beliefs About “Normal” Childhood Sexual Behaviors. *Child Abuse & Neglect*. 1998 Apr 1;22(4):289–304.
19. Friedrich WN, Fisher J, Broughton D, Houston M, Shafran CR. Normative sexual behavior in children: a contemporary sample. *Pediatrics*. 1998 Apr;101(4):E9.
20. Nguyen M, Murphy T. MIRTAZAPINE FOR EXCESSIVE MASTURBATION IN AN ADOLESCENT WITH AUTISM. *Journal of the American Academy of Child & Adolescent Psychiatry*. 2001 Aug 1;40(8):868–9.
21. Kul M, Baykan H, Kandemir H. A Case of Excessive Masturbation Treated with Aripiprazole. *Bulletin of Clinical Psychopharmacology*. 2013 Jan 1;24:1.
22. Coskun M. Effectiveness of Mirtazapine in the Treatment of Inappropriate Sexual Behaviors in Individuals with Autistic Disorder. *J Child Adolesc Psychopharmacol*. 2009;19(2):203–65.
23. Sabri H. Excessive masturbation in children and adolescents with autistic disorder: efficacy of escitalopram in three cases. *Alpha Psychiatry* [Internet]. 2009 [cited 2023 Jan 20];10. Available from: <http://alpha-psychiatry.com/en/excessive-masturbation-in-children-and-adolescents-with-autistic-disorder-efficacy-of-escitalopram-in-three-cases-132017>
24. Albertini G, Polito E, Sarà M, Di Gennaro G, Onorati P. Compulsive Masturbation in Infantile Autism Treated by Mirtazapine. *Pediatric Neurology*. 2006 May 1;34(5):417–8.