



## **Dysphagia as presenting symptom of myasthenia gravis: a case series of successful outcome in multidisciplinary approach**

**Anton Haryono\*, Rery Budiarti, Muyassaroh**

Otolaryngology Department of Medical Faculty, Universitas Diponegoro/Dr. Kariadi General Hospital, Semarang, Indonesia

### **ABSTRACT**

Submitted : 2019-10-07  
Accepted : 2020-02-17

Dysphagia can be caused by mechanic or neurologic disorders. Neurologic dysphagia is commonly related to cerebrovascular disease, parkinson disease, amyotropic lateral sclerosis, tardive dyskinesia, and myasthenia gravis (MG). About 15-40% dysphagia occurred in MG generalized type. Only 6% MG with dysphagia were reported as a single symptom. The case reports aimed to demonstrate the role of otolaryngologist in multidisciplinary approach of the MG management. Two cases of MG were reported. First case was a 33 years old woman with moderate MG generalized type with ocular, dysphagia, and disarthria symptoms and second case was a 46 years old man with acute severe MG with crisis. Management therapy was applied according to onset and severity of MG. Acetylcholinesterase (AChE) and corticosteroid were administered for the first case, whereas therapeutic plasma exchange (TPE) for second case. In conclusion, disfagia in MG can be accompanied with other symptom, therefore its management should be based on the severity in order to give a positive result.

### **ABSTRAK**

Disfagia dapat disebabkan oleh gangguan mekanik maupun motorik. Disfagia akibat gangguan saraf umumnya dikaitkan dengan penyakit cerebrovaskuler, parkinson, amyotropic lateral sclerosis, tardive dyskinesia dan miastenia gravis (MG). Sekitar 15-40% disfagia terjadi pada MG tipe generalisata. Hanya 6% disfagia dilaporkan sebagai gejala tunggal pada MG. Laporan kasus ini bertujuan memberikan gambaran peran ahli THT dalam penatalaksanaan MG secara multidisiplin. Dua kasus disfagia akibat MG telah dilaporkan. Kasus pertama adalah wanita berumur 33 tahun dengan MG tipe generalisata derajat sedang dengan gejala ocular, disfagia dan disartria. Kasus kedua seorang pria berumur 46 tahun dengan MG akut berat dengan krisis. Penatalaksanaan terapi dilakukan menurut onset dan keparahan MG. Asetilkolinesterase (AChE) dan kortikosteroid diberikan untuk kasus pertama, sedangkan terapi pertukaran plasma (TPP) untuk kasus kedua. Dapat disimpulkan, disfagia pada MG dapat disertai gejala lain sehingga tatalaksananya harus diberikan sesuai derajat keparahan penyakit agar memberikan respon yang baik.

**Keywords:**  
myasthenia gravis;  
dysphagia;

## INTRODUCTION

Dysphagia is a symptom of various diseases due to congenital and/or certain systemic disorders. The prevalence of dysphagia ranges from 7-22% in people over 50 years. Risk factors for dysphagia are old age, gastric acid reflux, stroke, head and neck malignancy, head trauma, Parkinson's disease, multiple sclerosis, muscular dystrophy, and myasthenia gravis (MG).<sup>1,2</sup> Myasthenia gravis is a rare autoimmune disease that causes muscle weakness. The disorder underlying this disease is the presence of antibodies that attack the nicotinic receptors in the neuromuscular junction. The prevalence of MG is about 20 cases per 100,000 lives. The highest incidence occurs in women over 40 years and even higher in men over 50 years.<sup>1</sup> Myasthenia gravis is classified into two types, namely ocular MG (10%) and generalized MG (90%). This disease can worsen in a matter of weeks or months.<sup>3,4</sup>

Dysphagia in MG cases is around 15 - 40% of patients with generalized MG. It can be a single symptom or as a accompanying symptom. Only 6% cases manifested dysphagia as a single symptom of MG.<sup>2</sup> Patients with dysphagia due to MG need appropriate management involving multidisciplinary approach in order to obtain a optimal result.<sup>2,5,6</sup> Assessment of dysphagia includes the existence of impaired swallowing function, the level of anatomy involved, and the underlying disease. Management of MG has several therapeutic modalities that can be given based on the severity and onset of MG.<sup>7</sup> The purpose of this paper was to report two cases of dysphagia in MG and their management using multidisciplinary approach.

## CASE REPORT

### Case I

A 33-year-old woman came with a chief complaint of hard to swallow. The patient had been complaining of difficulty in swallowing for two months that felt increasingly worsen. The patient must exert energy to swallow. The patient could only eat a little amount of porridge with the help of gulping water. The patient did not choke or cough when eating or drinking. The patient experienced nasal voice after talking for a long time. Shortness of breath sometimes felt. The patient was often sleepy and the eyelids closed themselves during the daytime. There was no blurred or double vision. No complaints of limb weaknesses. The patient had been experiencing nasal voice after talking for a long time for five months and the patient often felt sleepy during the day. The patient did not complain of difficulty in swallowing, limb weakness, or shortness of breath. The patient was already treated at the Neurology Department of the regional hospital to get 2 kinds of drugs and the complaints were improved. A history of such illness was denied. History of high blood pressure and history of diabetes mellitus (DM) were denied. No family member who had such disease previously. The patient was a housewife, with low socioeconomic status.

The physical examination found good general condition, good level of awareness. Vital signs were within normal limits. Mesocephalic head, symmetrical face, eyes were within normal limits. Neck lymph node enlargement was absent. Heart, lung, and abdomen examination results

were within normal limits. There were no limb weaknesses. At the time of the drinking test, the patient could drink 100 cc of water, more than 10 sec, and did not choke or cough while drinking and did not vomit.

Local status of ear, nose, and throat were within normal limits. Positive gag reflex. Laboratory blood tests were within normal limits. Chest x-ray in

anteroposterior and lateral position showed no abnormalities. The results of oesophagographic examination showed a partial narrowing of 1/3 proximal of the oesophagus, which concluded of suspected esophagitis. The main diagnosis was pharyngeal phase of dysphagia with the suspected neuromuscular abnormalities.

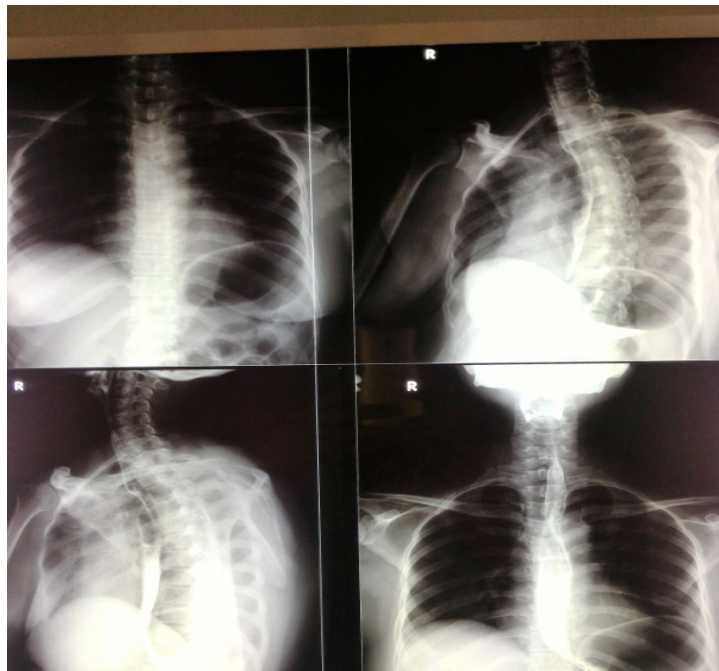

FIGURE 1. Esophagography

Consultation results from the Department of Neurology found good general condition, GCS of 15. Eyes: isochoric pupils, pupillary reflexes +/+, neck: stiff neck (-). Cranial nerve: within normal limits, sensibility, vegetative, and motoric functions were within normal limits. Watenberg test (+), count test: hypotonia (+). EMG examination showed a decrease of >20% on repetitive stimulation of 20 Hzin left flexor carpi ulnaris muscle which could support the diagnosis of MG. The Neurology Department assessments were dysarthria and dysphagia due to MG. The patient gave her informed consent prior and then underwent FEES examination. The results of FEES examination

showed pharyngeal phase of dysphagia due to neuromuscular disorder (MG), no aspiration signs were obtained. Patients were advised for soft diets and swallowing muscle physiotherapy. The results of MSCT Scan of thorax showed no abnormalities, no visible lung mass or mediastinal mass, no thymoma.

The patient was given RL infusion therapy of 20 drip per minute, injection of methyl prednisolone 125 mg/12 h IV for 4 days then tapering off, mestinon 60 mg/6 h orally. On day 4 of the treatment, the patient did not complain of difficulty in swallowing and there were no complaints of nasal voice. The patient was tested, and could drink 100cc in less than 4 sec. The patient was discharged on

the 7<sup>th</sup> day of treatment (after tapering off) and recommended to do a follow-up examination in one week with home therapy of 60 mg of mestinon/6 h orally.

One week later the control, the patient went to the ENT clinic and there were no complaints of difficulty in swallowing or nasal voice. Patients were given 60 mg/8 h of pyridostigmine therapy orally.

## **Case II**

A 46-year-old male consulted from the Department of Neurology with major complaints of difficult to swallow. The patient had been complaining of difficulty in swallowing for a week, even hard to swallow saliva, had nasal voice, and eyes closed themselves. The complaints increasingly aggravated and did not improve after patients took mestinon. The patient sometimes experienced shortness of breath and cough. The patient had been complaining of difficulty in swallowing for six months, swallowing food should be encouraged with drinking water, had nasal voice, and both eyes often closed themselves. Complaints felt worsen in the afternoon and evening. Patient went to the regional hospital and was given mestinon drugs taken 2 times a day. After taking the medicine, the complaint felt better.

A previous history of such illness was denied. History of high blood pressure and DM was denied. No family member who had such illness previously. The patient was an employee, treated using health insurance, socio-economic status was sufficient.

On physical examination found good general condition, good level of awareness. The patient had been installed NGT, vital signs were within normal limits. Mesocephalic head, symmetrical face, isochoric pupils, ptosis of right eye. Throat examination showed no gag reflex, nose and ears examination results were within normal limits. Heart, lungs, and abdomen examinations

results were within normal limits. There were no limb weaknesses. Physiological reflexes of the upper and lower limbs were normal. Pathological reflexes were not found. There were 9<sup>th</sup> and 10<sup>th</sup> nerve palsy. Watenberg test was positive.

Chest X-ray did not reveal any infiltrates on the lungs. MSCT scan of the head without contrast showed lacunar infarction in posterior crus of the left and right internal capsule. Results of blood laboratory examination showed hypernatremia (152 mmol/L), and other parameters were within normal limits. EMG showed a decrease in repetitive nerve studies in 3Hz, 8Hz, and 20 Hz stimuli that support the diagnosis of MG. Therapy was continued.

Clinical diagnosis: 9<sup>th</sup> and 10<sup>th</sup> cranial nerve palsy, dysarthria, dysphagia. Topical diagnosis: suspected neuromuscular junction, and etiological diagnosis: 1. MG. 2. Non-hemorrhagic stroke. Joint care with the department of Medical Rehabilitation, Clinical Nutrition, and ENT. Patients received O<sub>2</sub> of 3 L/min through nasal cannula, RL infusion of 20 drip per min, mestinon 1 tablet/6 h, prostigmin injection of 1 ampul/8 h IV, injection of methylprednisolone 125 mg/12 h IV, vitamin B1, B6, B12 1 tablet/8 h orally.

The assessment of the otolaryngology department was pharyngeal phase of dysphagia with the 9<sup>th</sup> and 10<sup>th</sup> cranial nerve palsy. Fiberoptic endoscopy evaluation of swallowing was conducted with the result of pharyngeal phase of dysphagia from neuromuscular abnormalities, silent aspiration was obtained. NGT is maintained. One week of the treatment, the patient could not swallow saliva resulting in salivary retention and shortness of breath. The patient was transferred to the ICU due to the threat of respiratory failure and MG crisis. The chest X-ray showed duplex pleural effusion and perihilar infiltrate. The therapy was continued with O<sub>2</sub> of 10 L/min through mask and nebulisation was done. Patients were programmed

for therapeutic plasma exchange (TPE) 6 times every 2-3 days. After the first TPE, the patient underwent improvement, complaints of shortness of breath were reduced, nasal noise was reduced, difficulty in swallowing was reduced and ptosis was improved. After the 5<sup>th</sup> TPE, methylprednisolone injection was tapered off for 3 days and the patient was given mestinon 60 mg/6 h orally. The patient's clinical condition was improved after the 6<sup>th</sup> TPE and the NGT was removed.

FEES examination for evaluation of therapy was conducted after TPE was completed. The test results showed no sign of dysphagia. The patient was discharged with mestinon therapy 60 mg/ 6 h orally. He had given his written informed consent before.

## DISCUSSION

Patients with dysphagia need a comprehensive examination from the history of illness, physical examination including neurological examination, and laboratory examination. Laboratory examinations include the detection of acetylcholine receptors (AChR) which can help to look for the causes of dysphagia due to MG, measurement of muscle enzymes for inflammatory myopathy, or thyroid function tests to enforce toxic myopathy.<sup>3</sup> Another supportive examinations for dysphagia are barium esophagography, videofluoroscopic swallowing study (VFSS), fiberoptic endoscopic evaluation of swallowing (FEES) test, upper endoscopy, and esophageal manometry.<sup>3</sup>

Myasthenia gravis is a rare autoimmune disease that causes muscle weakness. The disorder underlying this disease is the presence of antibodies that attack the nicotinic receptors in the neuromuscular junction.<sup>2,5</sup> The prevalence of MG is about 20 cases per 100,000 lives. The highest incidence occurs in women over 40 years and even higher in men over 50 years.<sup>2</sup>

The typical clinical feature of MG is fluctuating muscle weakness, especially after activity. The weaknesses include weakness of the eye and facial muscles, namely ptosis, diplopia and facial muscle weakness. Bulbar muscle weaknesses are nasal sounds, nasal regurgitation, difficulty in chewing, difficulty in opening the jaw, difficulty in swallowing or coughing when eating or drinking which can cause aspiration complications. Muscle weakness occurred in the upper limb is more frequent than in the lower limb. Respiratory muscle weakness, intercostal and diaphragmatic muscles weakness, causes CO<sub>2</sub> retention and hypoventilation, which can cause neuromuscular emergencies.<sup>6</sup> Both of the cases above showed pharyngeal phase of dysphagia which was caused by neuromuscular disorder.

Clinical classification of MG according to Osserman can be divided into five groups i.e. 1) Ocular MG, which only attacks the ocular muscles, accompanied by ptosis and diplopia. Very mild, no cases of death; 2) Mild generalized MG, slow onset, usually in the eyes, gradually spread to the skeletal and bulbar muscles. The respiratory system is not affected. The response to pharmacology therapy is good. Low mortality rate; 3) Moderate generalized MG, gradual onset and is often accompanied by ocular symptoms, then continues to get more severe with the attack of all the skeletal and bulbar muscles. Dysarthria, dysphagia, and difficulty of chewing are more evident than in mild myasthenia gravis. The respiratory muscles are not affected. The response to pharmacology therapy is less satisfactory and patient's activity is limited, but the mortality rate is low; 4) Acute severe MG, rapid onset with the severe weakness of the skeletal and bulbar muscles accompanied by the start of breathing muscles weakness. The disease usually develops maximally within six months. Poor response to pharmacology therapy. The incidence of miastenic, cholinergic, and combined

crisis are high. High mortality rate; 5) Advanced severe MG, arises at least 2 years after the onset of symptoms of group I or II. MG develops slowly or suddenly. The response to drugs and the prognosis is poor.<sup>6,7</sup>

Case I was classified as moderate generalized MG, in which patients had ocular symptoms with dysarthria and dysphagia. The patient have a good treatment response. Case II was classified as acute severe MG where the patient had a MG crisis and had a poor response to the administration of anticholinesterase inhibitors and improved after TPE was done.

The cause of MG is the presence of antibodies to the nicotinic type of AChR receptor (anti-AChR). The amount of AChR in the postsynaptic membrane is reduced due to the presence of anti-AChR. Anti-AChR is found in 80-90% of the MG patients. The cause of antibody production is based on the majority theory which states that about 80% of patients with MG have abnormalities in the thymus or thymoma.<sup>6</sup>

A simple examination, Ptosis, can be performed to establish a diagnosis of MG. Ptosis can be assessed by closing the eyelid in 30 sec or less when the patient is told to look up at one point (Watenberg test). Bulbar muscle weakness can be assessed by having the patient count to 50, then there will be nasal or weak voice. Respiratory muscle weakness can be assessed by asking the patient to take a deep breath and exhale strong breath through the nose, a weak breath and cough accompanied by tachypnea or tachycardia can support the diagnosis of MG.<sup>7</sup>

Investigations to establish MG diagnosis include 1) Assessment of acetylcholine anti-receptor antibodies. These antibodies are specific for MG and are very useful for establishing the diagnosis. These antibody titers are elevated in 90% of patients with MG in groups IIA and IIB, and 70% in group I. These antibody titers generally correlate

with the severity of the disease. 2) Skeletal anti-muscle antibodies, these antibodies are found in more than 90% of patients with thymoma and approximately 30% of patients with MG. Patients who have no antibodies in their serum and also no anti-acetylcholine receptor antibodies, then the possibility of thymoma is very small. 3) Tensilon (edrophonium chloride) test, tensilon is a cholinesterase inhibitor. This test is very useful if the examination of anti-acetylcholine anti-receptor antibodies cannot be done, or the test results are negative while clinically still suspected of MG. If there are no side effects after giving 1-2 mg tensilon intravenously, then 5-8 mg of tensilon is injected again. The reaction is considered positive if there is a clear improvement in muscle strength (for example within 1 min), disappearance of ptosis, the arm can be held in a longer abduction position, and increased vital capacity. 4) Prostigmin test, prostigmin of 0.5-1.0 mg mixed with 0.1 mg of atropine sulphate are injected intramuscularly or subcutaneously. The test is considered positive if symptoms disappear and energy improves. 5) Repetitive nerve stimulation test, a decrease in the amplitude of the combined muscle action potential with repeated stimulation of the peripheral nerve with a frequency of 3 Hertz (decremental response). 6) Single fiber EMG test, the method is more sensitive, there is an increase in the interpotential interval.<sup>6,8</sup>

Both of the reported cases obtained positive Wartenberg test, positive speech test, decreamenton repetitive stimulation test that supported the diagnosis of MG. MG management has 4 choices, namely: improving neuromuscular transmission with AChE inhibitor such as pyridostigmine (mestinon), treatment of acute exacerbations with TPE, immunoadsorption, and intravenous immunoglobulin, immunosuppression, and thymectomy. Myasthenia gravis therapy options can be given according to the onset of the disease.<sup>6</sup>

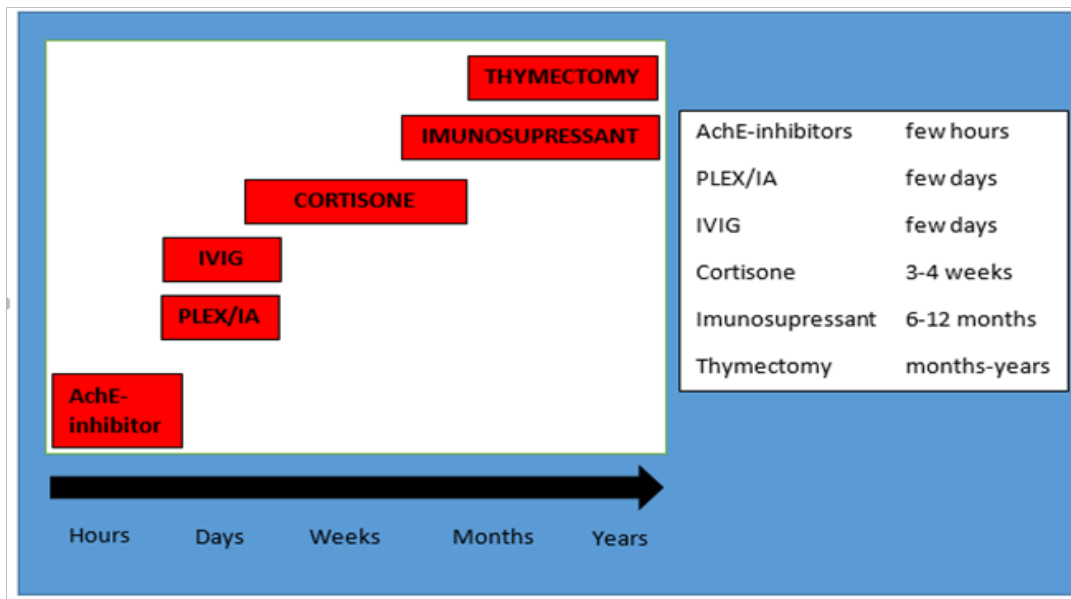


FIGURE 2. The choice of MG therapy according to the onset of the disease.<sup>6</sup>

Acetylcholinesterase inhibitors, work by inhibiting the formation of the cholinesterase enzyme which functions to break down acetylcholine, thereby indirectly increasing acetylcholine levels. Giving AChE can improve muscle weakness that occurs within hours but does not affect the course of the disease. High doses of AChE can cause “cholinergic crisis” with symptoms of miosis, bradycardia, hypersalivation, bronchoconstriction, lacrimation and sweating.<sup>6</sup>

Immunosuppressants can be used in MG therapy. Azathioprine is still the first choice for long-term immunosuppressants. Immunosuppression therapy such as azathioprine can be used on MG with an onset of several months. Corticosteroids are cheaper immunosuppressants. At the beginning of corticosteroids therapy, there is a risk of worsening of the disease. Long-term corticosteroid therapy must be avoided. Other immunosuppressant agents are cyclophosphamide and methotrexate.<sup>6</sup>

Plasmapheresis and intravenous immunoglobulin can be used in

myasthenic crisis. The plasmapheresis technique separates plasma from cells using membrane filtration or centrifugation. The cell is re-infused immediately after the cell plasma is removed. Albumin, colloids, crystalloids are used to maintain fluid volume and balance. Plasma exchange has high limitations and morbidity, so special equipment and trained personnel are needed. High doses of immunoglobulin are given intravenously and can be given on severe MG.<sup>6</sup>

Non-pharmacological therapy can be given to MG patients. This therapy can be in the form of exercise therapy, namely extensive joint motion exercises, breathing exercises in the form of inspiration breathing muscle exercises to strengthen the breathing muscles, pursed lip breathing and abdominal breathing, resistance and strength training which were proven effective for muscle diseases, occupational therapy to train how the movements are performed effectively, speech therapy in patients who experience facial and throat muscle weakness, and counseling therapy.<sup>7</sup>





Patient I was given AChE and corticosteroid therapy. Administration of therapy was according to the patient's MG degree and onset of the disease in order to eliminate MG complaints quickly. Patient II had an acute severe MG, the patient did not respond to AChE and corticosteroid administration. The patient experienced improvement by administering TPE which was the treatment of choice for acute exacerbation of MG. Both patients were consulted to the Medical Rehabilitation department to get physiotherapy to support the success of MG therapy.

## CONCLUSION

It is concluded that in 2 cases of dysphagia with MG, it is necessary to determine the degree of the disease that would determine the management. The first case receives oral AChE and corticosteroids therapy and give a good response. The second case is given oral and intravenous AChE and corticosteroids therapy, and does not experience improvement. Giving plasmapheresis give a good response. Multidisciplinary collaboration of otolaryngologist, neurologist and other disciplines are needed to obtain an optimal results.

## ACKNOWLEDGEMENT

We would like to thank patients who have been subjects in this study. There is no conflict of interest.

## REFERENCES

1. Kuhn MA, Belafsky PC. Functional assessment of swallowing In: Johnson JT, Rosen CA, editors. *Bailey's head and neck surgery-otolaryngology*, 5<sup>th</sup> edition. Philadelphia: Lippincott Williams & Wilkins, 2014:825-36.
2. Ramalho S, Pereira S, Oliveira P, Morais H, Lima N, Conde A.

Dysphagia as a presenting symptom of myasthenia gravis: case report. *Int J Otolaryngol Head Neck Surg* 2014;3:23-5.

<https://doi.org/10.4236/ijohns.2014.31005>

3. Ho S & Liu A. A co-occurrence of serologically proven myasthenia gravis and pharyngeal-cervical-brachial variant of Guillain-Barre syndrome. *Case Report Neurol Med* 2019; 4695010.  
<https://doi.org/10.1155/2019/4695010>
4. Marshal M, Mustafa M, Crowley P, McGovern R, Ahem E, Ragab I, *et. al.* Misdiagnosis of myasthenia gravis presenting with tongue and palatal weakness. *Oxford Medical Case Reports* 2018;8:235-7.  
<https://doi.org/10.1093/omcr/omy052>
5. Kumai Y, Miyamoto T, Matsubara K, Yamashita S, Ando Y, Orita Y. Assessment of oropharyngeal swallowing dysfunction in myasthenia gravis patients presenting with difficulty in swallowing. *Auris Nasus Larynx* 2019; 46(3):390-6.  
<https://doi.org/10.1016/j.anl.2018.10.004>
6. Liabres M, Molina FJ, Miralles F. Dysphagia as the sole manifestation of myasthenia gravis. *J Neurol Neurosurg Psychiatry* 2005; 76(9):1297-300.  
<https://doi.org/10.1136/jnnp.2004.038430>
7. Aslam M, Vaezi MF. Dysphagia in elderly. *Gastroenterol Hepatol* 2013;9(12):784-95.
8. Pavel G, Niewa S, Mihailescu G, Davidescu I, Anton R, Ciurea R. Myasthenia gravis-problems in diagnosis. a case presentation. *Romanian J Neurol* 2013;12:40-2.
9. Sieb JP. Myasthenia gravis: an update for the clinician. *Clin Exp Immunol* 2014;175(3):408-18.  
<https://doi.org/10.1111/cei.12217>
10. Henning S, Schroeter M. SOP Myasthenia gravis. *Neurol Res Pract*

- 2019; 1:19.  
<https://doi.org/10.1186/s42466-019-0023->
11. Rowin J. Approach to the patients with suspected myasthenia gravis or als : a clinician's guide. *Am Acad Neurol* 2009;15:13-34.  
<https://doi.org/10.1212/01.con.0000300006.49351.2c>
  12. Knuijt S, Kalf JG, Swart BJM, Drost G, Hendricks HT, Geurts ACH, *et al*. Dysarthria and dysfagia are highly prevalent among various types neuromuscular diseases. *Disabil Rehabil* 2014;36:1285-9.  
<https://doi.org/10.3109/09638288.2013.845255>
  13. Ha JC, Richman DP. Myasthenia gravis and related disorders: pathology and molecular pathogenesis. *Bioch Biophys Acta* 2015; 1852(4):651-7.  
<https://doi.org/10.1016/j.bbadis.2014.11.022>.
  14. Khadilar SV, Chaudhari CR, Patil TR, Desai ND, Jagiasi KA, Bhutada AG. Once myasthenic, always myasthenic? Observations on the behavior and prognosis of myasthenia gravis in a cohort of 100 patients. *Neurol India* 2014;62(5):492-7.  
<https://doi.org/10.4103/0028-3886.144438>.
  15. Farmakidis C, Pasnoor M, Dimachkie MM, Barohn RJ. Treatment of myasthenia gravis. *Neurol Clin* 2018; 36 (2): 311-7.  
<https://doi.org/10.106/j.ncl.2018.01.011>
  16. Sanders DB, Wolfe GI, Narayanaswarni P, MGFA Task Force on MG Treatment Guidance. Developing treatment guidelines for myasthenia gravis. *Ann NY Acad Sci* 2018; 1412(1):95-110.  
<https://doi.org/10.1111/nyas.13537>