



## Diagnosis approach, treatment, evaluation and fertility preservation in patient with Herlyn-Werner-Wunderlich syndrome: a case report

Lathifa Nadhya Indraswari, Nuring Pangastuti\*, Akbar Novan Dwi Saputra, Anis Widayarsi

Departement of Obstetry Ginekology Fakultas Kedokteran Kesehatan Masyarakat dan Keperawatan, Universitas Gadjah Mada Yogyakarta

### ABSTRACT

Submitted: 2022-06-05  
Accepted : 2022-12-31

Herlyn-Werner-Wunderlich (HWW) syndrome is a very rare female congenital anomaly of urogenital tract. The definite etiology of HWW syndrome is still unknown. It may be caused by the abnormal development of Mullerian and Wolffian ducts. The characteristic triad of this syndrome includes didelphys uterus, obstructed hemivagina, and ipsilateral renal agenesis, recently known as Obstructed Hemivagina and Ipsilateral Renal Anomaly (OHVIRA) syndrome. A 17 y.o. presented with intermittent lower abdominal pain. Physical examination revealed in normal limit. From the ultrasonography examination, it was found uterus didelphys with left hemiuterus hematometra, hematocolpos, with normal anatomy and function of the right kidney, but there was no left kidney. From pelvic magnetic resonance imaging (MRI) and laparoscopy showing a complete duplication of the uterus from the horn to the cervix with no connection between the two uterine cavities. Both ovaries were normal. The right fallopian tube was normal. The left tube was enlarged, attached to the uterus and the left ovary. No left kidney was found. From the previous surgery, there was a misdiagnosed with brown cyst. Physical examination such as rectal toucher often missed, regardless it can be used to determine some differential diagnosis. MRI is most accurate for providing details regarding the altered anatomy and for identifying associated hematocolpos, hematosalping or hematometra for HWW syndrome cases. The laparoscopy guiding diagnostic and operative management of the vaginal septectomy procedure was performed. In conclusion, misdiagnosis of HWW syndrome can be occurred on ultrasound examination. MRI is an examination that is considered appropriate to help confirm the diagnosis. Laparoscopy can be used with the aim of establishing a diagnosis or in surgical management, in this case, a septectomy is performed.

### ABSTRAK

Sindrom Herlyn-Werner-Wunderlich (HWW) merupakan kelainan kongenital saluran urogenital perempuan yang sangat jarang terjadi. Etiologi pasti dari sindrom HWW masih belum diketahui, tetapi mungkin disebabkan oleh perkembangan abnormal dari duktus Mullerian dan Wolffian. Tiga karakteristik sindrom ini termasuk uterus didelphys, obstruksi hemivagina, dan agenesis ginjal ipsilateral, yang dikenal sebagai sindrom *Obstructed Hemivagina and Ipsilateral Renal Anomaly* (OHVIRA). Seorang perempuan usia 17 tahun, dengan keluhan nyeri perut bawah intermiten. Pemeriksaan fisik didapatkan dalam batas normal. Dari pemeriksaan ultrasonografi ditemukan uterus didelphys dengan hematometra hemiuterus kiri, hematokolpos, dengan anatomi dan fungsi ginjal kanan normal, tetapi tidak didapatkan ginjal kiri. Dari *magnetic resonance imaging* (MRI) panggul dan laparoskopik menunjukkan duplikasi lengkap rahim dari tanduk ke leher rahim tanpa hubungan antara kedua rongga rahim. Kedua ovarium normal. Tuba fallopi kanan normal. Tuba kiri membesar, menempel pada rahim dan ovarium kiri. Tidak ditemukan ginjal kiri. Dari operasi sebelumnya, terdapat misdiagnosis dengan diagnosis kista coklat. Pemeriksaan fisik seperti *rectal toucher* sering terlewatkan,

### Keywords:

Herlyn-Werner-Wunderlich syndrome; obstructed hemivagina and ipsilateral renal anomaly (OHVIRA) syndrome; diagnosis; MRI; septectomy

\*corresponding author: [nuring\\_nw@yahoo.co.id](mailto:nuring_nw@yahoo.co.id)

padahal dapat digunakan untuk menentukan beberapa diagnosis banding. MRI paling akurat untuk memberikan rincian mengenai anatomi yang berubah dan untuk mengidentifikasi adanya hematokolpos, hematosalping atau hematometra pada kasus sindrom HWW. Prosedur septektomi dilakukan dengan panduan laparoskopi diagnostik sekaligus sebagai terapi pembedahan. Simpulan, misdiagnosis sindrom HWW dapat terjadi pada pemeriksaan USG. MRI merupakan pemeriksaan yang dianggap tepat untuk membantu menegakkan diagnosis. Laparoskopi dapat digunakan dengan tujuan untuk menegakkan diagnosis atau dalam tatalaksana pembedahan, dalam hal ini dilakukan septektomi.

## INTRODUCTION

Herlyn-Werner-Wunderlich (HWW) syndrome is a rare female congenital anomaly with estimated occurrence is about 0.1–3.8%. This syndrome occurs as a result of the failure of the lateral and vertical fusion of the Mullerian duct at 9 weeks' gestation.<sup>1</sup> The exact etiology is still unexplained. It may be caused by abnormality development of Mullerian and Wolffian ducts. There is incomplete resorption of the septum in the uterus or vagina in the embryonic period. This condition is defined as uterus didelphys and blind hemivagina associated with ipsilateral renal agenesis, which also known as obstructed hemivagina and ipsilateral renal anomaly (OHVIRA) syndrome.<sup>1-3</sup>

Herlyn-Werner-Wunderlich syndrome is an inherited disorder with a defect in the caudal portion of the mesonephric duct. The majority of cases of HWW syndrome (66%) has right-sided obstruction, with accompanying ipsilateral renal agenesis.<sup>4</sup> The estimated overall prevalence of Mullerian Duct anomaly (MDA) is 2–3% of women. Uterus didelphys create 11% of MDAs in which associated renal anomalies are presented in approximately 43%.<sup>5-8</sup>

The syndrome is classified by complete or incomplete obstruction of the vagina as classification 1 (completely obstructed hemivagina) and classification 2 (incompletely obstructed hemivagina). The clinical findings in

these two types are distinctly different.<sup>2</sup> From the classification 1, the uterus behind the septum is completely isolated from the contralateral uterus, and no communication is presented between the duplicated uterus and vagina. Hematokolpos may occur only a few months after menarche. Hematometra and hematosalpinx occurred in some more severely affected patients, as well as bleeding in the periaidnexal and peritoneal space. Patients with this classification have an earlier age of onset, with a short time from menarche to present acute symptom of abdominal pain, fever, and vomiting. Classification 1 is divided into classification 1.1-with blind hemivagina, there is no communication between the duplicated uterus and vagina; and classification 1.2-cervicovaginal atresia without communicating uteri, cervix behind the septum is atretic or maldeveloped.<sup>2</sup>

From the classification 2, there is a small communication exists between the two vaginas, which makes the vaginal cavity behind the septum incompletely obstructed. The uterus behind the septum is completely isolated from the contralateral uterus. The menses can outflow through the small communication, but the drainage is impeded. Some cases of this syndrome may go unnoticed for months or even years after menstruation.<sup>9</sup> These patients have a later age onset with chief complaint of purulent or bloody vaginal discharge that often comes years after

menarche. Classification 2 is divided into classification 2.1-partial reabsorption of the vaginal septum, there is a small communication exists between two vaginas with resultant incomplete obstruction; and classification 2.2-with communicating uteri, there is a small communication exists between two duplicated cervixes with a completely obstructed hemivagina.<sup>2</sup>

Hence, we presented a case of a female patient with HWW syndrome. A diagnosis approach, treatment, evaluation and fertility preservation were presented.

## CASE

A 17 y.o. female, presented with intermittent left lower abdominal pain. She denied nausea, vomiting, fever, abdominal distension or abdominal mass. The menarche had occurred 3 years before, her cycles were regular and the menstrual bleeding usually lasted about 4–5 days with dysmenorrhea. There was history of urinary disorders including micturition difficulty. From previously ultrasonography examination, she was suspected brown cyst then the doctor did laparotomy hysterotomy drainage with vaginal cross incision almost 1 year ago. After 5 months later she felt left lower abdominal pain again, bloody vaginal discharge with odor smell. Yet,

she denied recent weight loss, change in bowel habits, and sexual activity. She also had no history of diseases.

From physical examination including rectal and external genitalia examination, the results were within normal limits. Actually on usual cases it can be found abnormal rectal examination that is an extraluminary mass in the anterior rectum, originating from the hematocolpos in the obstructed hemivagina. A laboratory examination of complete blood and urine sample were in normal limits. There were no signs of urinary tract infection. From the trans-abdominal ultrasound that has been done, the results are as shown in FIGURE 1. There was didelphys uterus, the left hemiuterus size 9.5x4x1x4.6 cm with hematometra (+), while the right one size 4.1x3.1 cm and no hematometra. Hematocolpos was also found with the size 6.3x5.9x4.9cm, septum thickness was 5.8 mm, distance between introitus and interseptum was 4.7 cm, right kidney (+), left kidney was not visualized.

Pelvic MRI with contrast as shown in FIGURE 2 was carried out uterus didelphys, two vagina, left obstructed hemivagina, bilateral hidrocolpos with minimal bilateral hidrometra because of chronic hemorrhage. Other abnormality was agenesis left kidney which line to HWW syndrome.

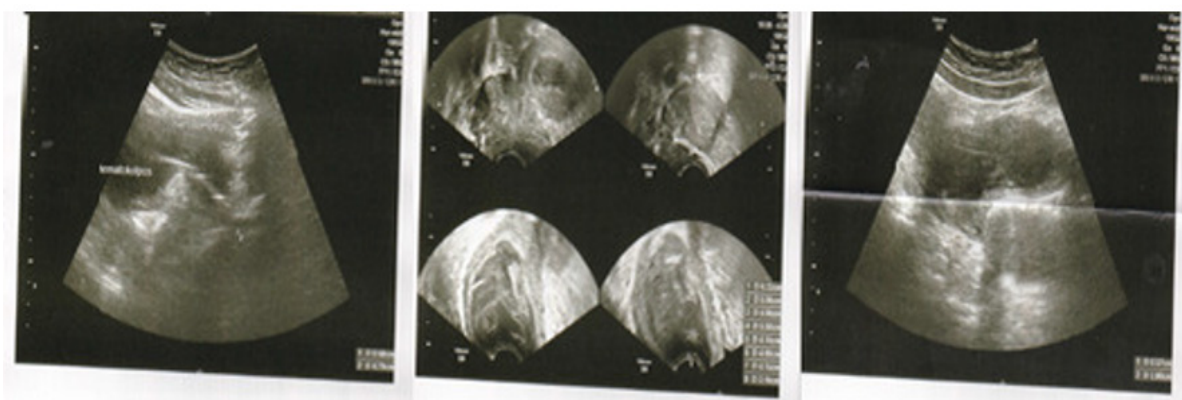


FIGURE 1. Trans abdominal ultrasonography (didelphys uterus, left hemiuterus with hematometra, right hemiuterus without hematometra)



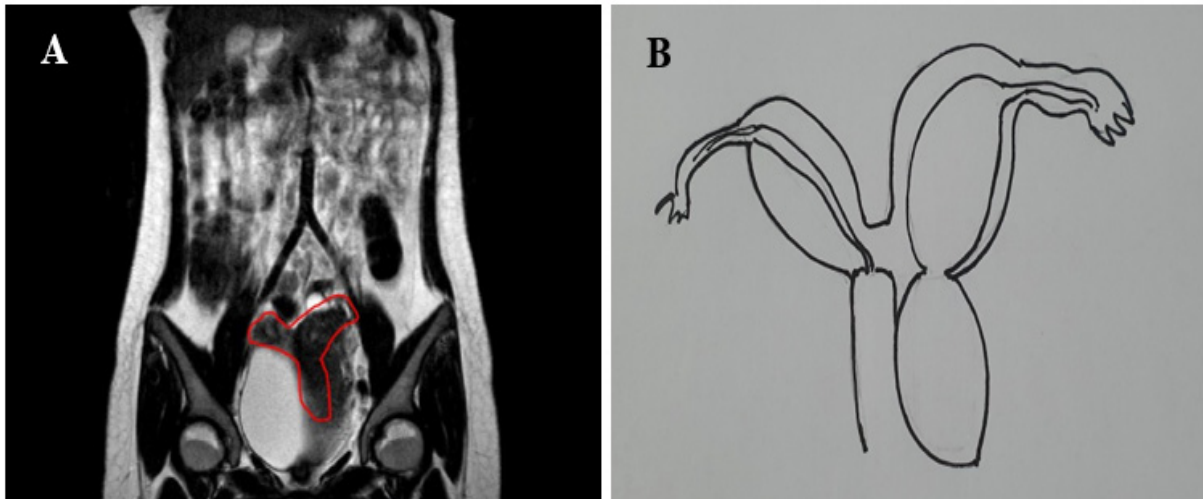


FIGURE 2. Pelvic MRI with kontras (A. didelphys uterus; B. schematic of the uterus didelphys with hematometra on the left hemiuterrus)

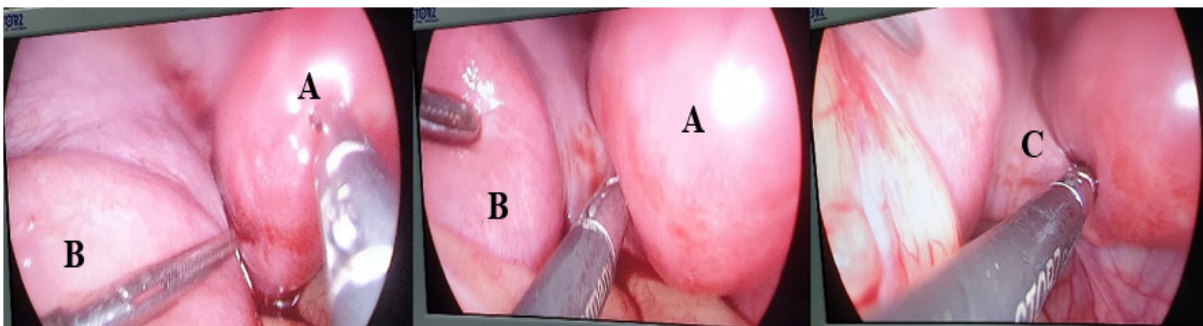


FIGURE 3. Laparoscopic shows didelphys uterus (A. right hemiuterus; B. left hemiuterus; C. cervix area tissue between right and left hemiuterus)

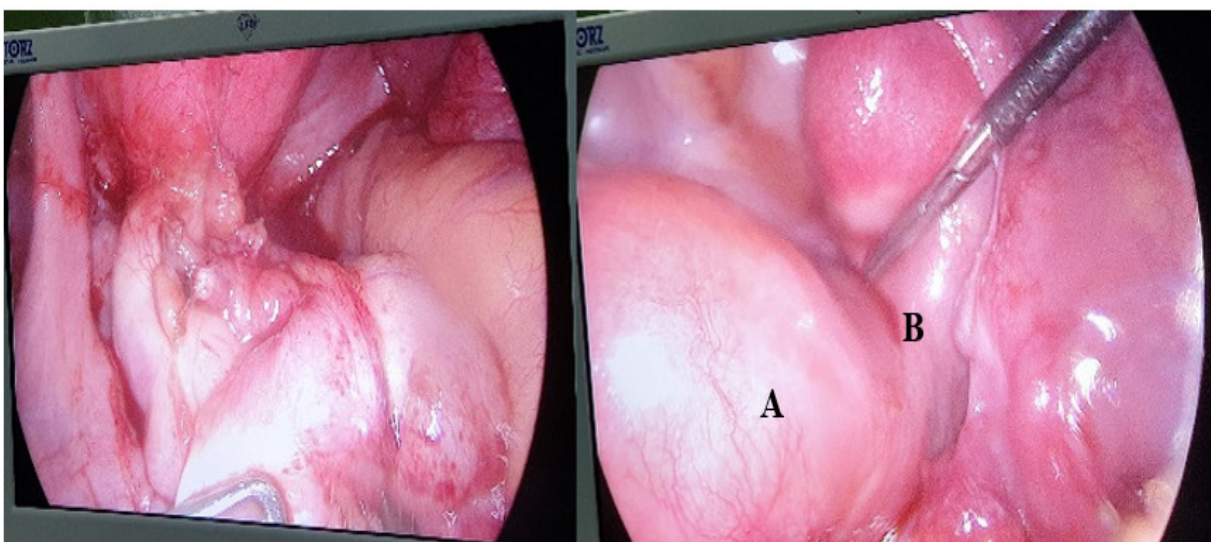


FIGURE 4. Laparoscopic shows (A) left hematometra and (B) left hydrosalping

## DISCUSSION

In the case report, the misdiagnosed from the previous ultrasonography may be caused by appearance left hematometra which pushed the other hemivagina looked like brown cyst. For the diagnosis of this syndrome, both ultrasound and MRI are very useful imaging techniques.<sup>10</sup> MRI is more accurate than hysterosalpingography (HSG) and ultrasound in the detection of acute and chronic complications.<sup>11</sup> MRI is an examination that is considered appropriate to help confirm the diagnosis of HWW syndrome or other congenital abnormalities. In HWW syndrome, the condition of renal agenesis can be diagnosed in childhood. The MRI procedure can confirm the presence of a uterine septum without any additional abnormalities. This is due to its ability to accurately demonstrate the anatomical structure of the pelvis and its vascularity.<sup>12,13</sup>

Vaginal septectomy procedure was performed over the entire length of the longitudinal vaginal septum, from the vaginal introitus to between the two uterine cervixes, about 7cm long. Sutures were made to the base of the septectomized vaginal tissue, to ensure that future adhesions would not occur. The septectomy procedure can be performed by excision of the septum by laparosteroscopy.<sup>13</sup> The report and systematic literature review from Moruzzi *et al.*,<sup>14</sup> in 2020 proposed a guideline for intraoperative laparoscopic ultrasonography as an innovative approach for use in complex female genital malformations.

The condition of the uterus didelphys with each uterine cavity has a depth of 8 cm, and both uterine cervix that appear normal, do not need to be corrected at the time of vaginal septectomy. Long-term follow-up is required, although it is said that up to 87% of pregnancies can occur, even 62% of them can reach term

gestation and undergo uncomplicated delivery.<sup>5</sup> There are no specific recommendations regarding mode of delivery in cases of HWW syndrome or in other congenital abnormalities. Women with uterine defects have an increased risk of complications in pregnancy and during delivery. Some of these complications include premature labor, low birth weight babies, and various conditions that require delivery to end with sectio caesarea. Each case has conditions that are different from other cases and must receive appropriate attention.<sup>15</sup>

Herlyn-Werner-Wunderlich syndrome or OHVIRA syndrome is a rare female congenital anomaly due to development of Mullerian and Wolffian ducts. The HWW syndrome diagnosis can be established with history taking, physical examination and appropriate diagnostic tools. Physical examination such as rectal toucher often missed, regardless it can be used to determine some differential diagnosis. MRI is most accurate for providing details regarding the altered anatomy and for identifying associated hematocolpos, hematosalping or hematometra for HWW syndrome cases. Surgical intervention by vaginal septectomy is performed to relieve symptoms, provide better reproductive for fertility preservation. For further evaluation can be conducted by vaginal patency examination periodically, HSG, and hysteroscopy.

## CONCLUSION

Misdiagnosis of HWW syndrome that occurred on ultrasound examination in the reported case may be due to the presence of a left hematometra pushing on the other side of the vagina to look like a chocolate cyst. MRI is an examination that is considered appropriate to help confirm the diagnosis of HWW syndrome or other congenital abnormalities. The use of laparoscopy be done with the

aim of establishing a diagnosis or to assist in surgical management. Surgical intervention by vaginal septectomy is performed to relieve symptoms, provide better reproductive for fertility preservation.

## ACKNOWLEDGEMENTS

The case was presented at Indonesian Urogynecology Association (*Himpunan Uroginekologi Indonesia/HUGI*) Virtual Meeting 2021 in Conjunction with 2<sup>nd</sup> AOFOG Urogynecology Webinar.

## REFERENCES

1. David A, Gudi SN, Shankar R. Herlyn–Werner–Wunderlich syndrome: premenarche. *J South Asian Feder Obstet Gynaecol* 2017; 9(2):207-10. <https://doi.org/10.5005/jp-journals-10006-1496>
2. Zhu L, Chen N, Tong JL, Wang W, Zhang L, Lang JH. New classification of Herlyn-Werner-Wunderlich syndrome. *Chin Med J (Engl)* 2015; 128(2):222-5. <https://doi.org/10.4103/0366-6999.149208>
3. Anonym. Management of acute obstructive uterovaginal anomalies: ACOG Committee Opinion No. 779. *Obstet Gynecol* 2019; 133(6):e363-71. <https://doi.org/10.1097/AOG.0000000000003281>
4. Liang HI, Fu SC, Yin CH, Chang CC. Herlyn–Werner–Wunderlich syndrome: an unusual case with presentation of menorrhagia. *Taiwan J Obstet Gynecol* 2020; 59(6):948-51. <https://doi.org/10.1016/j.tjog.2020.09.026>
5. Del Vescovo R, Battisti S, Di Paola V, Piccolo CL, Cazzato RL, Sansoni I, *et al.* Herlyn-Werner-Wunderlich syndrome: MRI findings, radiological guide (two cases and literature review), and differential diagnosis. *BMC Med Imaging* 2012; 12:4. <https://doi.org/10.1186/1471-2342-12-4>
6. Gholoum S, Puligandla PS, Hui T, Su W, Quiros E, Laberge JM. Management and outcome of patients with combined vaginal septum, bifid uterus, and ipsilateral renal agenesis (Herlyn-Werner-Wunderlich syndrome). *J Pediatr Surg* 2006; 41(5):987-92. <https://doi.org/10.1016/j.jpedsurg.2006.01.021>
7. Park NH, Park HJ, Park CS, Park SI. Herlyn-Werner-Wunderlich Syndrome with unilateral hemivaginal obstruction, ipsilateral renal agenesis, and contralateral renal thin GBM disease: a case report with radiological follow-up. *J Korean Soc Radiol* 2010; 62(4):383-8. <https://doi.org/10.3348/jksr.2010.62.4.383>
8. Behr SC, Courtier JL, Qayyum A. Imaging of müllerian duct anomalies. *Radiographics* 2012; 32(6):E233-50. <https://doi.org/10.1148/rg.326125515>
9. Pittokopitou S, Kathopoulos N, Protopapas A, Domali E. Herlyn–Werner–Wunderlich syndrome: report of a delayed diagnosed case with video presentation of the operative technique of vaginal septum resection. *J Obstet Gynaecol Res* 2021; 47(6):2242-5. <https://doi.org/10.1111/jog.14743>
10. Khaladkar SM, Kamal V, Kamal A, Kondapavulur SK. The Herlyn-Werner-Wunderlich syndrome – a case report with radiological review. *Pol J Radiol* 2016; 81:395-400. <https://doi.org/10.12659/PJR.897228>
11. Dias JL, Jogo R. Herlyn-Werner-Wunderlich syndrome: pre-and post-surgical MRI and US findings. *Abdom Imaging* 2015; 40(7):2667-82. <https://doi.org/10.1007/s00261-015-0421-0>
12. Ahmad Z, Goyal A, Das CJ, Deka D, Sharma R. Herlyn-Werner-Wunderlich syndrome presenting with infertility: role of MRI in diagnosis. *Indian J Radiol Imaging* 2013; 23(3):243-6. <https://doi.org/10.4103/0971-3026.120283>

13. Wdowiarz K, Skrajna A, Reinholz-Jaskólska M. Diagnosis and treatment of Herlyn-Werner-Wunderlich syndrome: a case report. *Prz Menopauzalny* 2021; 20(1):52-56. <https://doi.org/10.5114/pm.2021.104034>
14. Moruzzi MC, Bolomini G, Albanese M, Catena U, Romito I, Fagotti A, et al. Intraoperative endoscopic ultrasound guided surgical treatment of Herlyn-Werner-Wunderlich syndrome: case report and a systematic literature review. *Obstet Gynecol Res* 2020; 3:037-80. <https://doi.org/10.26502/ogr033>
15. Candenias LB, Davo DA, de Medina MPR, Orlando JM, Diaz ACL. Diagnosis and gestational follow-up in a patient with Herlyn-Werner-Wunderlich syndrome: a case report. *Taiwan J Obstet Gynecol* 2019; 58(4):560-5. <https://doi.org/10.1016/j.tjog.2019.05.023>