

Analysis of Tambau Water Pollution Levels Through Histopathology of Nilem Fish (*Osteochilus vittatus*)

Yusni Atifah^{1*}, Riri Putri Arianti¹, Vauzia Vauzia¹ & Rijal Satria²

¹Department of Biology, Faculty of Mathematics and Natural Sciences, Universitas Negeri Padang, Padang, West Sumatra, Indonesia

²Biodiversity of Sumatra Research Group, Department of Biology, Faculty of Mathematics and Natural Sciences, Universitas Negeri Padang, Padang, West Sumatra, Indonesia

Corresponding author, email: yusniatifah@fmipa.unp.ac.id

Submitted: 31 May 2023; Revised: 22 January 2024; Accepted: 06 March 2024; Published: 30 June 2024

ABSTRACT Tambau Lake is a lake used by the community to cultivate fish. The quality of lake waters can be reflected through animals that live in lake waters such as fish. Fish that have been polluted with pollutant compounds for a long period of time will experience structural and functional abnormalities, as well as changes in histological conditions. This study aims to determine the level of water pollution in Tambau Lake through histopathological studies of *Osteochilus vittatus* gills. This type of research is a descriptive analysis using a survey method of Tambau Lake and *Osteochilus vittatus*. Determination of *Osteochilus vittatus* and water samples using purposive random sampling method. Preparation using paraffin method and hematoxylin-eosin staining. The results of the study were then analyzed descriptively based on the level of damage to the gill tissue structure with the level of water pollution. The results of histopathological analysis on *Osteochilus vittatus* gill samples found damage to the presence of (a) edema (cell swelling), (b) hyperplasia which causes other damage, namely (clubbing tissue shaped like a baseball bat and thickening of cartilage) and (c) secondary lamella fusion which continues to become (telangiectasis) which indicates that Tambau Lake water is experiencing moderate - severe pollution. This is also in line with simple water quality results (physical, chemical and biological tests) which showed that the level of pollution was classified as severe.

Keywords: Fish gills; histopathology; Lake Tambau; water pollution

INTRODUCTION

Tambau Lake is located in Jorong Air Tawa Utara, Nagari Kampung Batu Dalam, Danau Kembar District, Solok Regency that used by the local community for fish cultivation. Based on our survey, the recent condition of Lake Tambau may already be at an alarming level due to the following conditions: this lake was surrounded by tea plantations with all insecticides and pesticides flows into the lake; as disposal of household waste; and used by some farmer for bathing of their livestock (i.e. cow and buffalos). We assumed that the harmful chemicals from these pollutants have a great effects on the water quality of Tambau Lake.

While the quality of water in Tambau Lake seems to be decreasing, this is found through our physical observations and lack of discharge of water flowing into the lake. This condition also explained by Atifah *et al.* (2023), that is the quality of the Tambau lake indicate the harmful pollutants through simple physical, chemical and biological tests. They also assumed that the water from this lake cannot be used as a drinking water. The pollution in water bodies will have an impact on the living things that live in it, including the fishes (Lewis *et al.*, 1980; Lawrence *et al.*, 2001; Banerjee *et al.*, 2011; Mandia *et al.*, 2013; Rao *et al.*, 2013; Otago Regional Council, 2015). However, the further testing needs to be done related to the pollution because the function of this lake as a source of fisheries, so it is feared that there is an accumulation of pollution in fish consumed by local residents.

The fish can be an indicator to determine the water quality in the water bodies. Fish is one of the aquatic biota that can be used as an indicator of the level of pollution that

occurs in the waters (Susanah *et al.*, 2013). The presence of pollutants in the body of fish is absorption mechanism through the gills, then digested through the its digestive system. The fish that have been contaminated with pollutant compounds for a long period of time will experience structural and functional abnormalities, as well as changes in histological conditions (Hardi, 2013). One of the fish organs that can experience these changes is the gills. In Wong & Marcus (2000) the gills have a wide and open surface which will result in the organ being the main target of exposure to toxic materials in the waters.

The present study aims to analysis the pollution levels of Tambau Lake through the histopathology of Nilem fish (*Osteochilus vittatus*). The type of fish chosen for several reasons, viz high rate of internal reproduction capture and possession process high adaptability on the environment (Hadi, 2020). The analysis of water pollution by using histopathology of fish was studied by several previous studies, heavy metal pollution in Riau's Kampar River caused changes in the histological structure of the gills of Baung fish (*Hemibagrus nemurus*) (Erlangga, 2007), the damage to the histology structure of *Prochilodus lineatus* gills due to water pollution (Camargo & Claudia, 2007), heavy metals causes a tissue damage to fish gills (Rennika *et al.*, 2013).

According to Authman *et al.* (2013) damage to the gills caused by polluted substances is divided into several levels, starting with edema, hyperplasia of the basal cells, lamellar fusion, fusion of all secondary lamellae, and loss of secondary lamellar structure and reducing filament. According to Ajia *et al.* (2019) the relationship between the level of structural damage to the gills and the level

of pollution is as follows Level of damage 0, No damage. Damage level 1, edema of the secondary lamella and detachment of epithelial cells from the underlying tissue (indicating that water fouling has occurred, but not yet water pollution). Damage level 2, hyperplasia of the basal cells of the secondary lamella (indicating mild contamination). Damage level 3, hyperplasia, fusion of two secondary lamellae (indicating mild contamination). Damage level 4, hyperplasia of almost all secondary lamellae (indicating moderate contamination). Damage level 5, loss of secondary lamella structure and filament damage (indicating severe pollution).

MATERIALS AND METHODS

Fish sample

The present study took place at Tambau Lake, Jorong Air Tawa Utara, Nagari Kampung Batu Dalam, Danau Kembar District, Solok Regency (1°1'19.2" S, 100°43'3.918" E, elevation ca. 1600 mdp). The field sampling conducted between August 2022 to January 2023. The specimen of Nilem fish (*Osteochilus vittatus*) was collected by traditional fishing, then the Making histology preparations of fish gills in the Zoology Laboratory, Department of Biology, FMIPA, Universitas Negeri Padang. There were 3 samples of Nilem fish with a length range of 17-21 cm and a weight range of 250-400 g examined in this study.

Histologic analysis

The fish was dissected and then removed the gills. Gills were observed in this study because Gills located outside and in direct contact with the air as a living medium for fish, then this is the organ the first time it is influenced by the air environment polluted by both dissolved and dissolved pollutants suspended. Then the gills samples experienced fixation process for 24 h using 10% formalin solution. The next steps were dehydrating, clearing, paraffin infiltration, blocking, cutting/sectioning, staining, and mounting. The histology analysis followed methods. A light microscope was used to analyze the samples. The histopathology analysis based on the Veta et al. (2014).

Data analysis

All Histopathological condition of the fish organs was described. According to Tanjung (1982), damage to the gills caused by polluted substances is divided into several levels, starting with edema, hyperplasia of the basal cells, lamellar fusion, fusion of all secondary lamellae, and loss of secondary lamellar structure and reducing filament. According to Ajiao et al. (2019) the relationship between the level of structural damage to the gills and the level of pollution is as follows Level of damage 0, No damage. Damage level 1, edema of the secondary lamella and detachment of epithelial cells from the underlying tissue (indicating that water fouling has occurred, but not yet water pollution). Damage level 2, hyperplasia of the basal cells of the secondary lamella (indicating mild contamination). Damage level 3, hyperplasia, fusion of two secondary lamellae (indicating mild contamination). Damage level 4, hyperplasia of almost all secondary lamellae (indicating moderate contamination). Damage level 5, loss of secondary lamella structure and filament damage (indicating severe pollution).

RESULTS AND DISCUSSION

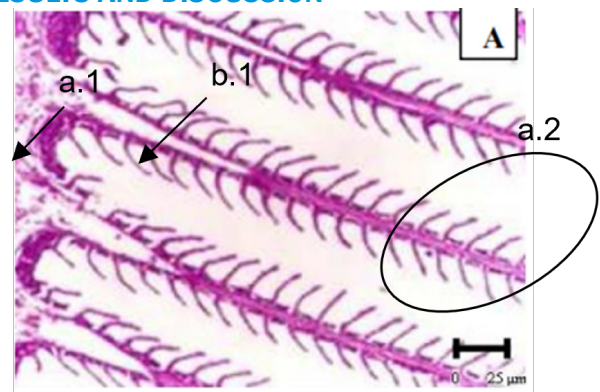


Figure 1. Histology of normal fish gills (400x magnification) (El-Shebly & Gad, 2011).

Water contaminated with heavy metals can affect the histological structure of the gills. Gills are organs with a wide and open surface, so they are one of the first organs exposed to toxic materials in the water. Normal gill organs are composed of lamellae and thin epidermal cells and rod-shaped supporting cells (pillar cells) that support blood flow to the gills (Kibenge & Strange, 2021).

Changes in the histological structure of Nilem fish gills can be used as an indicator of the level of water pollution in a body of water. From the observations, it was found that the water in Tambau Lake could be categorized as having experienced level 4 (moderate) - 5 (severe) pollution because the Nilem fish that was used as a sample had been found to experience changes in histological structure due to pollution that occurred in Tambau Lake. Gill damage happen if there is an increase in the number of cells originating from the lamella primary, migrate and accumulate on the lamella secondary, increasing the amount of one type or another various other cells. Epithelial cells can increase without additional connective tissue the observations are observed easy under a microscope by comparing it with fish gills normal condition The Histological changes experienced by Nilem fish in Tambau Lake are (a) edema (cell swelling), (b) hyperplasia which causes other damage, namely (clubbing tissue shaped like a baseball bat and thickening of cartilage) and (c) secondary lamellar fusion which continues to become (telangiectasis) (Figure 2).

This is in accordance to the statement of Dane & Sisman (2015) the damage to the histology of the gills is characterized by hyperplasia, then the pollution in a body of water is at level (4), namely moderate pollution. While according to Sipahutar et al. (2013), if lamellar fusion is found in the histology of the gills, then the waters have experienced pollution level (5), namely severe damage because lamellar fusion is an advanced stage of hyperplasia damage.

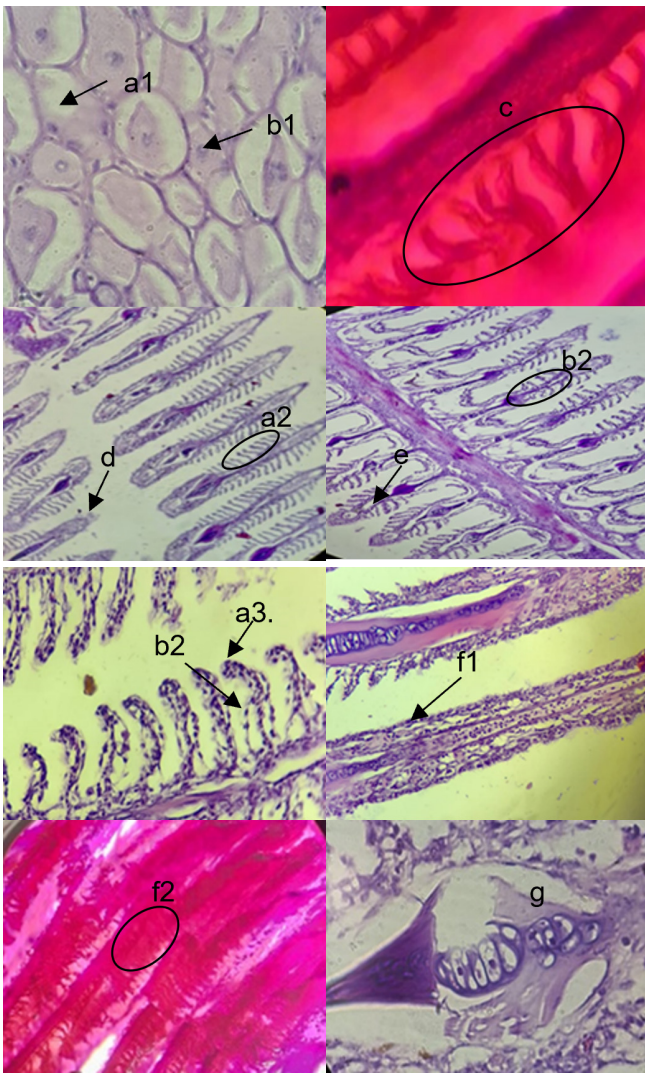


Figure 2. Histology of *Osteochilus Vittatus* gills (a1-a3) edema, 400x magnification (b1-b2) hyperplasia, 400x magnification (c) Secondary Lamellar Edema, 400x magnification (d) clubbing (100x magnification), (e) cartilage thickening (100x magnification), (f1-f2) secondary lamella fusion (100x magnification), and (g) telangiectasis (400x magnification).

The edema is a condition where fish gills experience swelling of cells in the tissue. Usually edema is often found in the secondary lamella (Figure a.1 - a.5). This is in accordance with the statement of Saputra et al. (2013) that edema in the lamella is a response of cells to protect themselves and survive due to exposure to chemical pollutants, ammonia poisoning and the presence of parasites attached to the gills. In addition, edema is also an early response in fish due to contaminated water (Yolanda et al., 2017). Therefore, if edema occurs continuously, it will cause other damage found in fish gills due to pollution in Tambau Lake. The hyperplasia can also be caused by excessive edema so that red blood cells come out of their capillaries and cells will experience detachment from their support (Susanah et al., 2013).

The hyperplasia is the excessive formation of tissue due to an increase in the number of cells, so that one cell with

another cell separates from each other and adaptive response to the body's defense against foreign bodies (parasitic infection) and bad media water (Figure. b.1 - b.2) (Rohde, 2005; Robert, 2001; Kalaiyarasi et al., 2017). The hyperplasia can also result in thickening of the epithelial tissue at the end of the filament which exhibits a baseball-like shape ("distal clubbing") or thickening of the tissue located near the base of the lamellae (basal hyperplasia) (Ersa, 2008). In the observation results of the present study, only one filament was identified as having 'clubbing'. However, this condition is a sign that the fish gills experiencing the circulation failure and extensive bleeding, then if this process continues continuously can cause fish death (Figure. d. and e.) (Jumria et al., 2017) The hyperplasia can result from various chemical pollutants and heavy metals especially Cadmium (Cd), Cuprum (Cu) and Zinc (Zn). The fish exposed to heavy metals, pesticide detergents and nitrophenols show separation between epithelial cells and the underlying system of pole cells which can lead to the collapse of the secondary lamellar structure, then cause an increase in the number of chlorid cells (Olurin et al., 2006; Suparjo, 2010). According to Ersa (2008), another cause of gill hyperplasia, lamellar thickening and fusion is nutritional deficiency. Robert (2001) also said that if hyperplasia occurs continuously, it will result in lamellar fusion.

The lamellar fusion in gill tissue itself is the fusion of two or more tissues due to epithelial tissue damage (Figure c.1-c.2). The lamellar fusion occurs due to an increase in hyperplasia pathology continuously and causes the filling of the space between secondary lamellae by new cells which then triggers attachment on both sides of the lamella (Sipahutar et al., 2013). If this condition continues, it will affect negatively to the respiration process. If the fish gills have experienced lamella fusion, it is meaning that this condition in an advanced stage of hyperplasia damage (Mandia, 2020).

Beside the histological changes that have been found in the gills, we also identified telangiectasias (Figure f). The continuous phase of hyperplasia will cause to lamella fusion and telangiectasia (Juanda, 2022). Telangiectasia is damage due to edema and hyperplasia which causes one part to swell and the other part to shrink, resulting in a narrowing of the blood vessels (Tandjung, 1982). This condition will strongly affected the blood circulation in the fish body. We assumed that the histological structure changes of Nile Fish in the Tambau lake due to the presence of toxic compounds. This is in accordance with Lestari et al. (2018) which states that the gills themselves are the first organ that can be directly exposed to toxic substances because the gills are in direct contact with the water during the respiration process. The gills have a large and open surface which will result in the organ being the main target of exposure to toxic substances in the waters (Wong & Marcus, 2000).

In the present study, we also conducted a simple test of water quality in the Tambau Lake, as knowledge regarding the condition of lake water quality as reflected in the concentration values of several water quality parameters. This simple test based following steps by Idrus (2018) simple physical tests; simple biological tests and

simple chemical tests.

Samples (lake water) of 50 ml were put into an Erlenmeyer, each air temperature was measured then 25 ml of distilled water was added, and the changes that occurred were noted in the form of changes in color, turbidity, temperature and odor. As a control, 25 ml distilled water in an Erlenmeyer flask without sample. The results of the simple physical quality test was showed that the water with a cloudy color and temperature of 27.4 °C, then its change after adding distilled water to slightly clear and the temperature changes to 26.2 °C. The change in color to clear and the decrease in water temperature after being given distilled water is because distilled water has a function as a control agent. In addition, tests were carried out on the odor of Tambau Lake water which has a rather pungent odor.

Then a simple chemical test was conducted. In 100 mL of air sample from each lake in an Erlenmeyer flask, 50 mL of tea water was added, and left overnight in open conditions before observing. The pH of Tambau Lake water after this treatment is five. This indicates that the lake water has acidic levels. The lower the pH value, the higher the solubility of heavy metals so that the toxic effects of metals will increase. The pH in water that increases will generally be followed by a lower solubility of the metal compound (Sukoasih & Widiyanto, 2017). The Lake water samples that have been mixed with tea also cause black clumps, dark discoloration and there is a layer of oil on the surface of the water which indicates poor water quality. The faster the changes that occur in tea water was indicated the higher the chemical content of the water.

Finally, a simple biological test was conducted where each water sample was put into a clear glass bottle and left for five days and the changes were observed, and the brown dirt deposits presence at the bottom of the container where the water was settled. The sediment found in the water sample bottle indicates the activity of microorganisms contained in the water. The microorganisms play a role in mineralization and sediment formation. The microorganisms become contaminants in water can cause damage or disruption to the life of aquatic biota and ecosystems. Certain microorganisms can be indicators of water pollution. Bacteria from the coliform group (*Streptococcus faecalis* and *Escherichia coli*) is the microorganisms that are often found in waters polluted by domestic waste (Fardiaz, 2003).

The results of this study can prove that histopathological changes in fish gills are one of the indicators that can be used to determine water quality in Tambau Lake. As found in the the prwsent study, the waters of Tambau Lake contaminated by pollution compounds at level 4 (moderate) to 5 (severe). This is also in line with research conducted by testing water quality simply (simple physics, chemistry, and biology tests) so that Tambau Lake water cannot be used as a source of drinking water and cannot be used as a source of fisheries by residents because it is feared that the accumulation of pollution in fish consumed by local residents.

CONCLUSION AND RECOMMENDATION

Conclusion

Based on the study of histopathology of Nile fish gills (*Osteochilus vittatus*), the conclusion of this study shows the level of water pollution in Tambau Lake is classified as heavy. Histopathology in Nile fish (*Osteochilus vittatus*) gill samples found are (a) edema (cell swelling), (b) hyperplasia which causes other damage, namely ('clubbing' tissue shaped like a baseball bat and thickening of cartilage) and (c) secondary lamella fusion which continues to become (telangiectasis) which indicates that Tambau Lake water is experiencing pollution level 4 (moderate) - pollution level 5 (severe). This is also in line with the results of simple water quality (physical, chemical, and biological tests) which show that the level of pollution is classified as heavy.

Recommendation

The community is expected not to make water in Tambau Lake the main source of drinking water and as a source of fisheries by residents because it is feared that there will be accumulation of pollution in fish consumed by local residents. It is necessary to conduct in-depth tests to determine the type of pollution found in Tambau Lake.

AUTHORS' CONTRIBUTION

All authors have contributed of the final manuscript as follow, YA and VV; compiled main conceptual ideas. RPA; compiled manuscripts, processed and analyxed data, critically revised articles. RS; conducted research and data collection.

ACKNOWLEDGEMENT

The researcher expresses gratitude to the Head of the Zoology Biology Laboratory, Department of Biology, Faculty of Mathematics and Natural Sciences, Padang State University, residents around Lake Tambau and thoses who helped of research.

REFERENCES

- Al Idrus, S.W. 2018. Analysis of water pollution using simple methods in Jangkuk, Kekalik and Sekarbela Rivers in Mataram City. Paedagoria: Journal of Educational Studies, Research and Development. 5 (2): 8-14. <https://doi.org/10.29303/jpm.v10i2.28>
- Atifah, Y., A. Achyar, G. Amanda, H.A. Afra & T.W. Marten. 2023. Simple detection of water pollution of Lake Talang and Lake Tambau Nagari Kampung Batu Dalam District Danau Kembar Solok Regency. EKSAKTA: Journal of Research and Learning MIPA. 8 (1): 105-111. <http://dx.doi.org/10.31604/eksakta.v8i1.105-111>
- Authman, M.M.N., S.A. Ibrahim, M.A. El-Kasheif & H.S. Gaber. 2013. Heavy metals pollution and their effects on gills and liver of the Nile Catfish inhabiting El-Rahawy Drain, Egypt. Glob Vet. 10 (2): 103-115.
- Banerjee, G. 2011. Underground pollution travel from leach pits of on-site sanitation facilities: a case study. Clean Technol Envir. 13 (3): 489-497. <https://doi.org/10.1007/s10098-010-0331-3>
- Bechmann, R.K., M. Amberg, A. Gomiero, S. Westerlund, E. Lyng, M. Berry, T. Agustsson, T. Jager & L.E. Burrige. 2019. Gill damage and delayed mortality of Northern shrimp (*Pandalus borealis*)

- after short time exposure to anti-parasitic veterinary medicine containing hydrogen peroxide. *Ecotoxicology and Environmental Safety*. 180 (3): 473-482. <https://doi.org/10.1016/j.ecoenv.2019.05.045>
- Brown, M.E. 1962. *The Physiology of Fishes*. Academy Press. Inc. New York.
- Camargo, M.M.P & C.B.R. Martinez. 2007. Histopathology of gills, kidney and liver of a neotropical fish caged in an urban stream. *Neotropical Ichthyology*. 5 (3): 327-336. <https://doi.org/10.1590/S1679-62252007000300013>
- Dane, H & T. Şişman. 2015. Histopathological changes in gill and liver of *Capoeta capoeta* living in the Karasu River, Erzurum. *Environmental toxicology*. 30 (8): 904-917. <https://doi.org/10.1002/tox.21965>
- Erlangga. 2007. Effects of Pollution of Kampar River Waters in Riau Province on Baung (*Hemibagrus nemurus*). Thesis. Graduate School.
- Ersa, I.M. 2008. Histopathological features of gills, intestines and muscles in tilapia (*Oreochromis mossambicus*) in Ciampea area, Bogor. Thesis. Bogor Agricultural University. Bogor.
- Fardiaz. 2003. *Water and Air Pollution*. Kanisius. Yogyakarta.
- Hadi, N., N.S. Ainy & M. Rais. 2020. Conservation of the upper Ciliwung River with native fish restocking activities (indigenous species). *Journal of Community Service in Teacher Training and Education (JPMHKP)*. 3 (1): 18-23.
- Hardi, E.H. 2003. Condition of Bontang Bay Waters: a Fish Immunology and Histology approach. Thesis. Graduate School. Bogor Agricultural University. Bogor. 71 p.
- Jiao, W., Q. Han, Y. Xu, H. Jiang, H. Xing & X. Teng. 2019. Impaired immune function and structural integrity in the gills of common carp (*Cyprinus carpio* L.) caused by chlorpyrifos exposure: Through oxidative stress and apoptosis. *Fish & shellfish immunology*. 86: 239-245. <https://doi.org/10.1016/j.fsi.2018.08.060>
- Juanda, S.J., I.T. Sianturi, Y. Kamlasi & M.F. Panuntun. 2022. Hematology and histopathology of catfish gills cultivated by local farmers in Noekele, East Kupang Regency. *BIO-EDU: Journal of Biology Education*. 7 (3): 190-198. <https://doi.org/10.32938/jbe.v7i3.3596>
- Jumria, A., N.C. Prihartini & A. Alfiah. 2017. Identification and histopathology *Flavobacterium columnare* in tilapia (*Oreochromis niloticus*). *Samakia: Journal of Fisheries Science*. 8 (2): 17-22. <https://doi.org/10.5281/zenodo.1059017>
- Kalaiyarasi, T., N. Jayakumar, P. Jawahar, B. Ahilan B A. Subburaj. 2017. Changes histological changes in gills and liver of sea spotted catfish, *Arius maculatus* from Sewage Disposal Site, Therespuram off South East Coast of Thothupudi, India. *Journal of Entomology and Zoological Studies*. 5 (5): 1710-1715. <https://www.entomoljournal.com/archives/2017/vol5issue5/PartV/5-5-63-159.pdf>
- Kibenge, F.S & R.J. Strange. 2021. Introduction to the anatomy and physiology of the major aquatic animal species in aquaculture. *Aquaculture Pharmacology*. Academic Press. <https://doi.org/10.1016/C2019-0-02736-7>.
- Lawrence, AR, Macdonald, DMJ, Howard, AG, Barret, MH, Pedley, S., Ahmed, KM, et al. Lawrence, A.R., D.M.J. Macdonald, A.G. Howard, M.H. Barret, S. Pedley, K.M. Ahmed. 2001. Guidelines for assessing groundwater risks from on-site sanitation. Commissioned report (CR/01/142) of the British Geological Survey.
- Lestari, W.P., N.I. Wiratmini & A.A.G.R. Dalem. 2018. Histological structure of fish gills (*Oreochromis mossambicus* L.) as an indicator of water quality of the nusa dua lagoon, Bali. *Symbiosis*. 6 (2): 45-49. <https://doi.org/10.24843/JSIMBIOSIS.2018.v06.i02.p03>
- Lewis, W.J., S. Foster & B. Drasar. 1980. Risk of groundwater pollution by on-site sanitation premises in developing countries: A review of the literature, International Reference Center for Sewage Disposal.
- Mandia, S., N. Marusin & P. Santoso. 2013. Histological analysis of kidney of asang fish (*Osteochilus hasseltii*) in Lake Maninjau and Singkarak, West Sumatra. *Journal of Biology, Andalas University*. 2(3): 194-200. <https://doi.org/10.25077/jbioua.2.3.%25p.2013>
- Mandia, S., S. Susanti & A.D. Maharani. 2020. Histopathological indicators of water pollution in the gills of tilapia (*Oreochromis niloticus* L.). *Bioconcetta*. 6 (2). <http://dx.doi.org/10.22202/bc.2020.v6i2.4147>
- Olurin, K.B., E.A.A. Olojo, G.O. Mbaka & A.T. Akindele. 2006. Histopathological responses of the gill and liver tissues of *Clarias gariepinus* fingerlings to the herbicide, glyphosate. *African Journal of Biotechnology*. 5 (24): 2480-2487. <https://academicjournals.org/journal/AJB/article-abstract/AB5A2C79133>
- Otago Regional Council. 2015. Groundwater contamination risk, septic tank density and distribution within Otago. Dunedin: Otago Regional Council.
- Rao, S.M., M. Sekhar & P.R. Rao. 2013. Impact of pit-toilet leachate on groundwater chemistry and role of vadose zone in removal of nitrate and *E-coli* pollutants in Kolar District, Karnataka, India. *In Environmental Earth Sciences*. 68 (4): 927-938. <https://doi.org/10.1007/s12665-012-1794-9>
- Rastogi, S.C. 2007. *Essentials of Animal Physiology 4th Ed*. New Age International (P) Ltd. New Delhi.
- Rennika, A & N. Abdulgani. 2013. Concentration and duration of exposure of organic and inorganic compounds in the gill tissue of mujair fish (*Oreochromis mossambicus*) under sub lethal conditions. *Pomits Journal of Science and Art*. 2 (2): 132-137.
- Robert, R.T. 2001. *Fish Pathology*. 3rd Edition. W.B. Saunders. London Edinburgh, Philadelphia, St. Louis, Sydney, Toronto. 472 p.
- Rohde, K. 2005. *Marine Parasitology*. CSTR Publishing. Australia.
- Saputra, H.M., M.N., Marusin & S. Putra. 2013. Histological structure of gills and hemoglobin levels of asang fish (*Osteochilus hasseltii* C.V) in Singkarak and Maninjau Lakes, West Sumatra. *Journal of Biology*. 2 (2): 138-144
- Sipahutar, L.W., D. Aliza, W. Winaruddin & N. Nazaruddin. 2013. Histopathological features of Tilapia gills that are kept in water temperatures above normal. *Journal of Medika Veterinaria*. 7 (1): 1-3.
- Solikhah, T & W. Trianik. 2015. Effect of surfactant on growth and histopathology of tilapia gills (*Oreochromis niloticus*) as learning material for class X high school students. *Jurnal Jupemasi PBI*. 248-255.
- Sukoasih, A & T. Widiyanto. 2017. The Relationship between temperature, pH and various distance variations with lead (Pb) levels in the Rompong River Water Body and Central Sokaraja Batik Industry Dug Well Water in 2016. *Buletin Keslingmas*. 36 (4): 360-368. <https://dx.doi.org/10.31983/keslingmas>

v36i4.3115

- Suparjo, M.N. 2010. Gill tissue damage of tilapia (*Oreochromis niloticus* L) due to detergents. *Journal of Fisheries Science and Technology*. 5 (2): 1-7.
- Susanah, U. A., K. Santosa & N.R. Utami. 2013. Microanatomical structure of milkfish gills in ponds of Tapak Area, Tugurejo Village, Tugu Semarang Subdistrict. *Bioscience: Journal of Biology & Biology Education*. 5 (1).
- Tandjung, H.S.D. 1982. The acute toxicity and histopathology of Brook Trout (*Salvelinus Fontinalis*, Mitchill) exposed to aluminum in acid water. Fordham University.
- Tandjung, H.S.D. 1983. Determination of toxicity of a pollutant in the aquatic environment. Faculty of Biology UGM, Yogyakarta.
- Veta, M., J.P.W. Pluim, P.J. Van Diest & M.A. Viergever. 2014. Breast cancer histopathology image analysis: A review. *IEEE transactions on biomedical engineering*. 61 (5): 1400-1411. <https://doi.org/10.1109/tbme.2014.2303852>
- Wong, C.K & H.W Marcus. 2000. Morphological and biochemical changes in the gills of tilapia (*Oreochromis mossambicus*) To ambient cadmium exposure. *Aquatic Toxicology*. 48 (20): 517-527. [https://doi.org/10.1016/S0166-445X\(99\)00060-0](https://doi.org/10.1016/S0166-445X(99)00060-0)
- Yolanda, S., R. Rosmaidar, N. Nazaruddin, T. Armansyah, U. Balqis & Y. Fahrimal. 2017. The effect of lead (Pb) exposure to the histopathology of Nile tilapia (*Oreochromis Niloticus*) gill. *Veterinary Student Scientific Journal*. 1 (4): 736-741.