

Case Report

The Successful Treatment of Toxocariasis in a Domestic Cat using Pyrantel Pamoate

Keberhasilan Pengobatan Toksokariasis pada Kucing Domestik menggunakan Pirantel Pamoat

Juni Claudia Dami¹, Luh Putu Eka Damayanti¹, Soedarmanto Indarjulianto^{2*}, Yanuartono²,
Dwi Priyowidodo³, Agustina Dwi Wijayanti⁴

¹Magister of Veterinary Science, Faculty of Veterinary Medicine, Universitas Gadjah Mada,
Yogyakarta, Indonesia

²Department of Internal Medicine, Faculty of Veterinary Medicine, Universitas Gadjah Mada, Yogyakarta,

³Department of Parasitology, Faculty of Veterinary Medicine, Universitas Gadjah Mada,
Yogyakarta, Indonesia

⁴Department of Pharmacology, Faculty of Veterinary Medicine, Universitas Gadjah Mada,
Yogyakarta, Indonesia

*Corresponding author, Email: indarjulianto@ugm.ac.id

Article received: December 8, 2022, revision: August 21, 2023, accepted: August 24, 2023

Abstrak

Toksokariasis adalah penyakit menular yang disebabkan oleh *Toxocara sp.* pada kucing yang mengakibatkan penurunan kondisi bahkan dapat menyebabkan kematian terutama pada anak kucing. Pirantel pamoat adalah obat cacing yang saat ini jarang digunakan dalam pengobatan toksokariasis. Tujuan dari penulisan makalah ini adalah untuk melaporkan keberhasilan pengobatan toksokariasis pada kucing menggunakan pirantel pamoat. Kucing domestik betina berumur 3 bulan dengan berat 1,3 kg yang menderita diare digunakan dalam penelitian ini. Pemeriksaan meliputi pemeriksaan fisik, dilanjutkan dengan pemeriksaan laboratorik berupa feses dan sampel darah. Hasil penelitian menunjukkan kondisi tubuh kucing kurus, kotoran pada mata, selaput lendir pucat, rambut kusam/rontok, dan diare dengan konsistensi feses encer. Pemeriksaan kucing menunjukkan adanya telur *Toxocara sp.* sebanyak 2.400 EPG dalam sampel feses, dan hasil pemeriksaan darah ditemukan bahwa kucing tersebut mengalami anemia normokromik normositik. Kucing didiagnosis menderita toksokariasis dengan prognosis *dubius*. Kucing diberi kaolin-pektin 1-2 ml/kg BB per oral 2 kali sehari selama 3 hari, injeksi multivitamin dengan dosis 0,5 ml secara intramuskuler, dan antelmintik pirantel pamoat dengan dosis 20 mg/kg BB per oral satu kali. Setelah 28 hari perawatan, kucing dinyatakan sehat berdasarkan kondisi fisik yang lebih baik, tidak diare, tidak ada telur cacing pada sampel feses, dan tidak anemia. Disimpulkan bahwa kucing yang terkena toksokariasis berhasil disembuhkan dengan pemberian antelmintik pirantel pamoat, sehingga obat ini masih direkomendasikan untuk pengobatan toksokariasis pada kucing.

Kata kunci: Antelmintika; kucing; pirantel; toksokariasis

Abstract

Toxocariasis was an infectious disease caused by *Toxocara sp.* in cats that lead to deterioration of the condition and can even cause death, especially in kittens. Pyrantel pamoate is an anthelmintic that is currently being abandoned for toxocariasis. The purpose of this paper is to report the success of toxocariasis treatment in a cat using pyrantel pamoate. Female domestic cat, 3 months old, weighing 1.3 kg suffering diarrhea was used in this study. The cat examined including a physical examination, followed by laboratory examination of fecal and blood samples. The results showed the cat's body condition was thin, eye was dirty, anemic mucous membranes, dull hair/loss, and diarrhea with watery stool consistency. The cat examination revealed the

presence of *Toxocara sp.* egg as much as 2,400 EPG in fecal sample, and the results of blood tests found that the cat had normochromic normocytic anemia. The cat was diagnosed toxocariasis with dubious prognosis. A cat treated with kaolin-pectin with 1-2 ml/kg BW orally 2 times a day for 3 days, multivitamin injection at a dose of 0.5 ml intramuscularly, and the anthelmintic pyrantel pamoate at a dose of 20mg/kg BW orally once. After 28 days of treatment, the cat was declared healthy based on better physical conditions, no diarrhea, no worm eggs in the fecal sample, and did not anemia. It concluded that cats with toxocariasis successfully cured by administering the anthelmintic pyrantel pamoate, so this drug is still recommended for the treatment of toxocariasis in cats.

Keywords: anthelmintic; cat; pyrantel; toxocariasis

Introduction

Helminthiasis is a disease that needs attention in cats. Helminthiasis is classified as a neglected disease because it does not cause serious clinical symptoms, except in severe and chronic infections (Soeharsono, 2007). The most helminthiasis case reported in cats is toxocariasis. Toxocariasis is an infectious disease caused by worms from the nematode group belonging to the order: Ascarididae, superfamily: Ascaridoidea, family: Toxocaridae, and genus: *Toxocara*. There are three species of *Toxocara sp.* that are very important in veterinary medicine, they are *Toxocara canis* which infects dogs, *Toxocara cati* infects kittens and adult cats, and *Toxocara vitulorum* infects calves and cattle (Sariego *et al.*, 2012).

Toxocariasis has been reported in various places around the world, especially in tropical and subtropical areas where the population has many dogs and cats. Toxocariasis does not only occur in pets but also in humans (zoonosis) with clinical manifestations of visceral and ocular toxocariasis (Joy *et al.*, 2017). The incidence of toxocariasis in humans is highly dependent on the incidence of toxocariasis in pets. The population of cats in Indonesia is quite high because of the relationship between cats and humans, considering that cats can act as reservoir hosts for humans (Kusnoto, 2005). Toxocariasis is one of the most common parasitic infections in humans in the world (Manurung and Lambok, 2012). Globally, toxocariasis has been found in many countries with a worldwide prevalence rate that can reach 40% or more (CDC, 2019).

The incidence of *Toxocara sp.* infection rate in cats in Indonesia based on reports has different percentages, including in Yogyakarta with a prevalence of 2.5% (Al Faiz, 2014),

Banyuwangi 23.9% (Suroiyah *et al.*, 2018), Bogor 35% (Murniati *et al.*, 2016), Denpasar 48.8% (Nealma *et al.*, 2013), and in Surabaya with a prevalence rate of 60.9% (Kusnoto, 2005). Cats can become infected by ingesting infective eggs in food and water. Clinical symptoms in cats with *Toxocara sp.* infections are anorexia, hair loss, abdominal swelling, vomiting, and diarrhea. Symptoms of cough may occur due to the migration of larvae through the respiratory system. Pneumonia can occur in young cats if there is larval migration. Large numbers of worms can cause decreased food absorption causing hypoalbuminemia, anorexia with an enlarged abdomen, and even in some cases, death may occur (Overgaauw and Knapen, 2013). Treatment of toxocariasis in cats is often ignored, making cats more complicated to treat. The administration of anthelmintics is one of the efforts to maintain the health of cats against infection of *Toxocara sp.* However, the administration of anthelmintics in the field is often not based on clinical and laboratory examinations of the patient. The selection of anthelmintics needed to be based on the type of worm that infects so that it is more effective and efficient, that is also to reduce the resistance of parasites to drugs. Administration of anthelmintic in cats according to the diagnosis and dose affects the incidence of toxocariasis (Palmer *et al.*, 2007). Pyrantel pamoate is an anthelmintic that is used widely in the treatment of worm infections caused by nematodes such as *Toxocara sp.* (Papich, 2010).

Pyrantel pamoate works by inhibiting the process of neuromuscular depolarization in worms, causing spastic neuromuscular paralysis and death. Pyrantel also works by inhibiting the cholinesterase enzyme, thereby increasing the

muscle contractions of the worms (Katzung, 1998; Wijaya, 2017). The toxocariasis diagnosis in the field is not always based on physical and laboratory examinations, and the administration of anthelmintics to cats is also rarely monitored. This paper aims to report the successful diagnosis of toxocariasis and its treatment in cat using pyrantel pamoate. This case report can be used as information as well as a reference in the diagnosis and therapy of toxocariasis in cats.

Materials and Methods

This case report used on a 3 months old female domestic cat weighing 1.3 kg who with watery diarrhea and weight loss. This research has obtained permission from the owner and received ethical approval from the Research Ethics Committee of the Faculty of Veterinary Medicine, Gadjah Mada University in Certificate Number: 0007/EC-FKH/Int./2021.

Physical and laboratory examination

Physically, the cat in this study was examined starting from anamnesis, general condition examination, body temperature, pulse and respiratory rate, hydration status, mucous membranes, skin and hair, auditory, optic, digestive, lymphatic, cardiovascular, uropoetic, genital, and locomotion systems (Widodo *et al.*, 2011; Englar, 2017; Dewandaru *et al.*, 2019; Indarjulianto *et al.*, 2022). Feces of the cat was taken for endoparasite examination and blood samples for hematological examination.

Examination of endoparasites in feces was carried out using native and flotation-centrifugation methods, followed by counting the number of worm eggs using the McMaster method (Cardillo *et al.*, 2014; Roeswandono *et al.*, 2019). Feces examination was carried out on day 0 before the administration of anthelmintics, and on days 7, 14, 21, and 28 after administration of the anthelmintics. Hematological examinations before and after treatment included counting the number of erythrocytes, hemoglobin, hematocrit, mean corpuscular volume (MCV), mean corpuscular hemoglobin (MCH), and mean corpuscular hemoglobin concentration (MCHC) (Cahyani *et al.*, 2019).

Diagnosis and treatment of toxocariasis

Based on the results of physical and laboratory examinations, the cat in this study was diagnosed with toxocariasis and treated with the anthelmintic pyrantel pamoate (Combantrin[®], PT. Pfizer, Indonesia) at a dose of 20 mg/kg body weight (PO), two times, on the 1st and 15th days (Plumb, 2008). The cat was also treated with Kaolin Pectin (Kaotin[®], Erela, Indonesia) at a volume of 1-2 ml/kg BW orally, twice a day for 3 consecutive days, with multivitamin injection (Biodin[®], PT Romindo Primavetcom, Indonesia) at a volume of 0.5 ml for 5 consecutive days intramuscularly. The progress of therapy was obtained for 28 days and evaluated based on the comparison of the results of the physical and laboratory examination from feces on days 0, 7, 14, and 28, as well as blood tests on days 0 and 28 after the administration of the anthelmintic. Evaluation of anthelmintic administration was carried out by calculating the percentage of the fecal egg count reduction test (FECRT).

Results and Discussion

The examination results in this study showed that the cat had diarrhea, with a body temperature of 38.6°C, pulse frequency 104 times/minute, respiration 24 times/minute, CRT 2 seconds, anemic conjunctiva, auditory discharge, and optic lacrimation. The results of the stool examination using the native and flotation-centrifugation methods, both found the presence of *Toxocara sp.* eggs with 2,400 EPG (Figure 1). The results of blood counts showed that before treatment, the cat had normochromic normocytic anemia (Table 1). Based on the history, physical examination, and laboratory

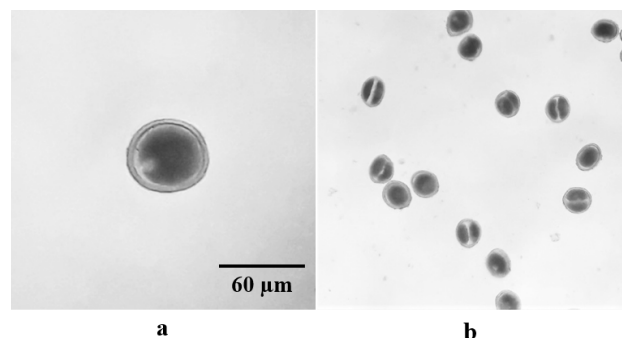


Figure 1. Eggs of *Toxocara sp.* (a) native method (1000x); (b) flotation-centrifugation (400x).

examination, the cat, in this case, was diagnosed with toxocariasis with a dubious prognosis.

Table 1. Hematological examination results before and after anthelmintic treatment

Parameters (units)	Cat		Referral Value (*)
	Before	After	
Erythrocyte (10 ⁶ /μL)	4,1 (L)	7,1 (N)	6,0 – 10,0
Hemoglobin (g/dL)	7,5 (L)	10,5 (N)	9,5 – 15,0
Hematocrit (%)	17,9 (L)	33,5 (N)	24,0 – 45,0
MCV (fl)	52,3 (N)	47,0 (N)	41,0 – 54,0
MCH (pg)	13,7 (N)	14,7 (N)	13,3 – 17,5
MCHC (%)	32,5 (N)	31,3 (N)	31,0 – 36,0

KTC: L= Low; N= Normal; MCV= Mean corpuscular volume; MCH= Mean corpuscular hemoglobin; MCHC= Mean corpuscular hemoglobin concentration. (*)= Tilley and Smith, 2011.

The clinical examination results before treatment in this study showed that the body temperature, pulse, and respiratory rate in cats were still within the normal range. Other physical examinations such as examination of the mucous membranes, general body condition, hair, and visual stools showed that the cat's mucous membranes looked anemic, and hair were dull and shed. Physical examination of the feces revealed yellowish brown with watery/liquid consistency and classified as type 7 diarrhea. Microscopic examination of the feces showed that *Toxocara sp.* eggs were found. In general, the species of *Toxocara* that infects cat is *T. cati*. Observations on eggs showed that *T. cati* eggs had a thick outer layer or wall, brown in color, round in shape with a size of 60 μm, this observation followed the explanation of Bowman *et al.*, (2002), regarding the morphology of *T. cati* eggs measuring 65x75 μm, subglobular round with thick walls, outer walls with lace-like holes and containing morula, while the inner walls of eggs consist of chitin, eggs are brown and do not have embryos when expelled with feces.

Clinical symptoms of cat toxocariasis by Lee *et al.*, (2010), were generally associated with the digestive tracts as diarrhea, vomiting, abdominal distended, and even cause intestinal obstruction in severe infections. Other clinical symptoms such as coughing can also occur if there is a migration of larvae through the respiratory system. The migration of larvae can cause pneumonia in young cats. Worms in large

numbers can cause a decrease in food absorption, and hypoalbuminemia occurs which results in emaciation with an distended abdomen, and even death in some cases (Overgaauw, 1997).

The clinical symptoms of by the cat in this study were diarrhea, emaciation, anemic mucous membranes, hair loss, and dullness. The emaciated condition experienced by the cat may be related to worms infection in the digestive tract which inhibit the absorption of nutrition interfere with the growth process, and cause weight loss. Supraptini (2013) reported that the presence of adult worms in the small intestine took nutrients, causing nutrient absorption in the intestine being not optimal. Diarrhea was caused by the damage of the intestinal mucous due to worm infection, failure to absorb nutrients due to damage to the intestinal villi, and thickened intestinal walls (Calista *et al.*, 2019). Clinical symptoms of hair loss in cat are associated with eating disorders that affect appetite. According to Widodo *et al.*, (2011), decreased appetite for a long time will showing abnormalities in the hair such as dry, rough, and easy to fall out/loose. Anemic mucous membranes were indication of anemia. Discolored mucous membranes can provide additional information for veterinarians to evaluate and determine the general condition of the animal (Widodo *et al.*, 2011). After 28 days of treatments, observation, and administration of anthelmintic, the results improved, the mucous membranes returned to normal, the body weight increased and the cat no longer had diarrhea.

Clinical symptoms that appear in the cat depend on the infection degree, age, and immunological status, the presence of multiple infections simultaneously also affects (Sheikh *et al.*, 2020). The infection degree of helminth can be obtained by counting the number of eggs per gram of feces (EPG) using the McMaster method. A cat with a mild infection degree has 1–199 EPG, a cat with a moderate infection rate has 200–999 EPG, and more than 1,000 EPG indicates a cat has a severe infection (Roeswandono *et al.*, 2019). The results of the fecal examination using the McMaster method showed that the cat was infected with *Toxocara sp.* with a severe infection. The results of the fecal examination in cats after being given the

anthelmintic pyrantel pamoate showed that worm eggs were not found anymore starting at the first week after treatment.

The results of the hematological examination of the cat before anthelmintic therapy, in this case, showed the presence of anemia as seen from the decrease in the value of erythrocytes, hemoglobin, and hematocrit. According to Salasia and Hariono (2014), anemia occurs as a condition in lower rates of hemoglobin and erythrocyte or both in blood circulation. It is interpreted that the cat has normochromic normocytic anemia. Signs of anemia are pale mucous membranes due to reduced blood volume, hemoglobin, and vasoconstriction conditions (Bijanti *et al.*, 2010; Wuhan, 2019). Anemia that occurs, in this case, is most likely due to a decrease in the absorption function of the proximal intestinal mucous membrane due to migration and invasion of *Toxocara sp.* in the small intestine. According to Panova *et al.*, (2021), anemia caused by *Toxocara sp.* is closely related to decreased Cobalt (Co), the active substance forming vitamin B12. Digestion and absorption of Cobalt occur through absorption in the proximal small intestine, if the concentration of Cobalt decreases it will affect the process of forming vitamin B12 which functions in the formation of red blood cells, optimizing nerve function and maintaining cat's healthy skin and hair.

Treatments the cat in this case, were to provide antidiarrheal, multivitamin, and anthelmintic therapy. Kaolin pectin has a mechanism of action by affecting the adsorbent, changing the viscosity of feces, absorbing toxins and bacteria in the digestive tract, and protecting the gastrointestinal mucous (Plumb, 2008). Anthelmintics administration has side effects that deteriorate diarrhea symptoms in cat, so anthelmintics are usually given after antidiarrheal administration. Pyrantel pamoate is an anthelmintic derivative of tetrahydro pyrimidine that can acting as a neuromuscular depolarizing inhibitory agent, causing paralysis of the parasites muscles and difficulty adhering to the intestinal wall. The worms then come out with feces (Wijaya, 2017).

The suitability of anthelmintics need to be considered to avoid the occurrence of worm resistance to anthelmintics used in the

field. Anthelmintic administration evaluation was conducted by calculating the percentage reduction in the number of fecal eggs or the fecal egg count reduction test (FECRT). Examination of feces before and after treatment of the anthelmintic pyrantel pamoate in the cat showed a FECRT value of 100%. The value of FECRT was used to estimate the number of eggs in the feces that decreases and the appropriate confidence interval, the results of this calculation can be used as a reference in determining the anthelmintic resistance status of animals (Coles *et al.*, 2006). In this study, the use of pyrantel pamoate anthelmintic shows a good therapeutic potential. Pyrantel shows limited absorption after oral administration, which indicates the presence and effectiveness of pyrantel in the digestive tract where adult nematode worms stay longer (Arion *et al.*, 2018).

Conclusion

Cat with toxocariasis successfully cured by administering the anthelmintic pyrantel pamoate, so this drug was still recommended for the treatment of toxocariasis in cat.

Acknowledgments

The authors would like to thank the Directorate of Research Universitas Gadjah Mada for the funding with contract number 3143/UN1.P.III/DIT-LIT/PT/2021.

References

- Al Faiz, N.M. (2014). Kejadian Toksokariasis Pada Kucing di Yogyakarta Berdasarkan Pola Pemeliharaannya. *Skripsi*. Fakultas Kedokteran Hewan Universitas Gadjah Mada, Yogyakarta.
- Arion, A., Fernández-Varón, E., Cárceles, C.M., Gagyí, L., and Ognean, L. (2018). Pharmacokinetics of praziquantel and pyrantel pamoate combination following oral administration in cats. *Journal of Feline Medicine and Surgery*. 20(10) pp 900-904.
- Bijanti, R., Gandul, A.Y., dan Retno, S.W. (2010). Buku Ajar Patologi Klinik Veteriner. Surabaya: Universitas Airlangga.
- Bowman, D.D., Hendrix, C.H., Lindsay, D.S.,

- and Barr, S.C. (2002). *Feline Clinical Parasitology*. Iowa State University Press, Ames, IA, USA.
- Cahyani, A.P., Suartha, I.N., dan Dharmawan, N.S. (2019). Laporan kasus: penanganan Dipylidiasis pada kucing anggora dengan Praziquantel. *Jurnal Sains dan Teknologi Peternakan*. 1(1): 20-24.
- Calista, R.M.D.P., Erawan, I.G.M.K., and Widyastuti, S.K. (2019). Laporan Kasus: Penanganan Toksokariasis dan Skabiosis pada Kucing Domestik Betina Berumur Enam Bulan. *Indonesia Medicus Veterinus*. 8(5) pp 660-668.
- Cardillo, N., Sommerfelt, I., Farina, F., Pasqualetti, M., Perez, M., Ercole, M., Rosa, A., and Ribicich, M. (2014). A *Toxocara cati* eggs concentration method from cats feces, for experimental and diagnostic purposes for experimental and diagnostic purposes. *Veterinary Parasitology*. 56: 198-205.
- (CDC) Control Disease and Prevention. (2013). Parasites - Toxocariasis (Also Known As Roundworm Infection). USA.
- Coles, G., Jackson, F., Pomroy, W., Prichard, R., von SamsonHimmelstjerna, G., Silvestre, A., and Vercruysse, J. (2006). The detection of anthelmintic resistance in nematodes of veterinary importance. *Veterinary Parasitology*. 136(3-4), 167-185.
- Dewandaru, R.A., Indarjulianto, S., Yanuartono., Nururrozi, A., Purnamaningsih, H., dan Rusmihayati. (2019). Diare disebabkan Infeksi *Escherichia coli* pada Anjing. *Journal of Tropical Animal and Veterinary Science*. 9(2): pp 38-43.
- Englar, R.E. (2017). *Performing The Small Animal Physical Examination*. 1st ed. John Wiley & Sons, Inc. Usa.
- Indarjulianto, S., Yanuartono, Y., Nururrozi, A., Raharjo, S., Purnamaningsih, H., Widiyono, I., Hartati, S., Dami, J.C., and Damayanti, L.P. (2022). Study of Digestive Tract Diseases in Cats. *In 7th International Conference on Biological Science (ICBS 2021)* pp. 494-497.
- Atlantis Press.
- Joy, A.T., Chris, O.I., and Godwin, N.C. (2017). Toxocariasis and Public Health: An Epidemiological Review. *Glob. J. Infect. Dis. Clin. Res.* 3, 28-39.
- Katzung, B.G. (1998). *Farmakologi Dasar dan Klinik Edisi VIII*. Jakarta : EGC. pp : 857-837.
- Kusnoto. (2005). Prevalensi toksokariasis pada kucing liar di Surabaya melalui bedah saluran pencernaan. *Media Kedokteran Hewan*. 21(1):7-11.
- Lee, A.C.Y., Schantz, P.M., Kazacos, K.R., Montgomery, S.P., and Bowman, D.D. (2010). Epidemiologic and zoonotic aspects of ascarid infections in dogs and cats. *Trends in Parasitology*. 26(4): 155-161.
- Manurung, R.S. dan Lambok, S. (2012). Infeksi *Toxocara sp.* pada hewan peliharaan di Kelurahan Padang Bulan tahun 2012. *EJournal*. Fakultas Kedokteran USU. 1(1):1-3.
- Murniati, S.E. dan Ridwan, Y. (2016). Prevalensi dan Faktor Risiko Infeksi *Toxocara cati* pada Kucing Peliharaan di Kota Bogor. Program Studi Kesehatan Masyarakat Veteriner Program Pascasarjana Fakultas Kedokteran Hewan Institut Pertanian Bogor. Bogor.
- Nealma, S., Dwinata, I.M., dan Oka, I.B.M. (2013). Prevalensi infeksi cacing *Toxocara cati* pada kucing lokal di wilayah Denpasar. *J. Indo. Med. Vet.* 2(4):428-436.
- Overgaauw, P.A. (1997). Aspect of *Toxocara* epidemiology: *Toxocariasis in dogs and cats*. *J. Parasitol.* 23(3):215-231.
- Overgaauw, P.A.M. and Knapen, F.V. (2013). Veterinary and public health aspect of *Toxocara spp.* *Vet. Parasitol.* 193 (4): 398-403.
- Palmer, C.S., Rebecca, J.T., Ian, D.R., Rusell, P.H., Aileen, E., Lyndon, W., Robert, R., and Andrew, T. (2007). The veterinary and public significance of hookworm in dogs and cats in Australia and the status

- of *A. ceylanicum*. *Vet. Parasitol.* 145:304-313.
- Panova, O., Khrustalev, A., Sysoeva, N., Baranova, M., Glamazdin, I., and Kryukovskaya, G. (2021). Standard Blood Tests Indicate Changes of Toxocariasis in Carnivores. International research conference on Challenges and Advances in Farming, Food Manufacturing, Agricultural Research and Education. *KnE Life Sciences*. pp 501–510.
- Papich, M.G. (2010). *Saunders Handbooks of Veterinary Drugs Small and Large Animal Third Edition*. Elsevier: USA. 252-253, 596-598.
- Plumb, C.D. (2008). *Veterinary Drugs Handbook*. 6th Ed. Minesota(US): Wiley, John and Sons.
- Roeswandono., Mussa, O.R.P.A., Pangaribuan, M.J.A., dan Palgunadi, B.U. (2019). Perhitungan Telur *Toxocara cati* dan Jumlah Sel Darah Putih pada Kucing Liar (*Felis catus*) di Dukuh Kupang Surabaya. *Jurnal Vitek Bidang Kedokteran Hewan*. 9: 18-23.
- Salasia, S.I.O., dan Hariono, B. (2014). *Patologi Klinik Veteriner*. Samudra Biru. Yogyakarta.
- Sariego, I., Kanobana, K., Rojas, L., Speybroeck N., Polman K., and Nunez, F.A. (2012). Toxocariasis in Cuba : A literature Review. *PMC journal*. Plos Neglected Tropical Disease: vol. 6.
- Sheikh, M.M., Tak, H., and Fazili, M.F. (2020). Gastrointestinal Helminths of Cat (*Felis catus*) In Kashmir Valley, India. *International Journal Of Scientific and Technology Research*. 9: 314-319.
- Soeharsono. (2007). *Penyakit Zoonotik pada Anjing dan Kucing*. Yogyakarta (ID): Kanisius Press.
- Supraptini, J. (2013). Kasus Toxocariasis pada Anjing di Rumah Sakit Hewan Pendidikan Universitas Airlangga. *Jurnal Klinik Veteriner*. 2 (1).
- Suroiyah, F.A., Hastutiek, P., Yudhana, A., Sunarso, A., Purnama, M.T.E., dan Praja, R.N. (2018). Prevalensi Infeksi *Toxocara cati* pada Kucing Peliharaan di Kecamatan Banyuwangi. *Jurnal Medik Veteriner*. 1(3) p 99.
- Tilley, L.P., and Smith, F.W.K. (2011). *Wiley-Blackwell's Five-Minute Veterinary Consult: Canine and Feline*. Wiley-Blackwell. USA.
- Widodo, S., Sajuthi, D., Choliq, C., Wijaya, A., Wulansari, R., dan Lelana, R.P.A. (2011). *Diagnostik Klinik Hewan Kecil*. Bogor (ID) : IPB Press.
- Wijaya, J.S. (2017). Perbandingan Efektivitas dan Efek Samping Albendazole dengan Kombinasi Mebendazole-Pyrantel Pamoat Untuk Terapi *Soil-transmitted Helminthiasis* Anak Sekolah Dasar Kecamatan Medan Tembung. *CDK*. 44(6): 253.
- Wuhan, Y.O.P. (2019). *Diagnosa Klinis, Hematologi, Molekuler Ehrlichiosis dan Karakterisasi Gen glta Ehrlichia canis pada Pasien Anjing di Yogyakarta*. Thesis. Fakultas Kedokteran Hewan. Universitas Gadjah Mada.