

Review

Splayed Leg in Birds: Diagnosis, Therapy, and Prevention

Splayed Leg pada Burung: Diagnosis, Terapi, dan Pencegahan

Rief Ghulam Satriya Permana¹, Soedarmanto Indarjulianto², Yanuartono^{2*}, Anggitya Nareswari¹,
Shafa Adea Puspitadesy³

¹Mindi Petshop and Petcare, Yogyakarta, Indonesia

²Department of Internal Medicine, Faculty of Veterinary Medicine, Universitas Gadjah Mada,
Yogyakarta, Indonesia

³Undegraduate Study Program of Veterinary Medicine, Faculty of Veterinary Medicine,
Universitas Gadjah Mada, Yogyakarta, Indonesia

*Corresponding author, E-mail: yanuartono@ugm.ac.id

Article received: August 3, 2023, revision: September 20, 2023, accepted: October 20, 2023

Abstrak

Splayed leg adalah kondisi kaki terentang ke luar atau ke samping dari posisi normalnya di bawah tubuh yang sering diderita burung muda. Gangguan ini biasanya dibiarkan tanpa perlakuan, karena dianggap sebagai kondisi cacat permanen yang tidak dapat diterapi, tanpa diperiksa penyebabnya. Beberapa *splayed leg* pada anakan burung dapat diperbaiki dengan memberikan perlakuan untuk kedua kaki mereka pada posisi yang benar. Diagnosis *splayed leg* secara dini dan dilanjutkan terapi yang tepat sangat diperlukan agar kondisi kaki dapat dipulihkan menjadi normal. Diagnosis dan terapi yang kurang tepat akan menyebabkan kaki burung menjadi cacat permanen, sehingga burung akan menderita seumur hidupnya. Diagnosis dan terapi kasus *splayed leg* telah dikembangkan dengan hasil yang bervariasi. Tujuan review ini mengulas diagnosis, terapi dan pencegahan kejadian *splayed leg* pada burung, yang dapat dipakai sebagai acuan memperbaiki kesejahteraan burung.

Kata kunci: burung; diagnosis; *splayed leg*

Abstract

Splayed leg is a condition where the legs are stretched outwards or sideways from their normal position under the body which is often suffered by young birds. This disorder is usually left untreated, because it is considered as a permanent disability condition that cannot be treated without examining the cause. Some of the splayed legs in chicks can be improved by treating both their legs in the correct position. Early diagnosis of splayed leg and continued appropriate therapy is needed so that the condition of the foot can be restored to normal. Incorrect diagnosis and therapy will cause the bird's feet to become permanently disabled, so the bird will suffer for the rest of its life. The diagnosis and treatment of splayed leg cases have been developed with varying results. The purpose of this review is to evaluate the diagnosis, therapy, and prevention of the occurrence of splayed legs in birds, which can be used as a reference to improve bird welfare.

Keywords: bird, diagnosis, splayed leg

Introduction

Splayed leg or what it is often called a straddle leg, is a term used to describe a leg that is stretched outwards or sideways from its normal position under the body resulting in problems with mobility and balance. This condition can involve one or both legs and ranges from mild to severe, which if not given therapy will result in permanently disabled life, and even death. This condition is common in nest boxes and often affects bird tillers. The causes of the splayed leg are genetic factors, innate from birth, slippery base, a large number of nestlings with a smaller nest size so that there is a buildup for a long time, and poor nutrition, poor condition, vitamin deficiency, and poor cage hygiene (Paspatsiros, 2012; Setiana *et al.*, 2018; Worell, 2018). Birds must get enough sunlight to meet their vitamin needs. Cages that are too densely populated which causes some birds to be on the edge of cage that is not exposed to sunlight, and this results in vitamin D deficiency among birds which can affect their growth (Setiana *et al.*, 2018). Several cases of the splayed leg have been reported in parrots, parakeets, and love birds. Clinical symptoms seen in the cases of the splayed leg are the formation of abnormal foot conditions, decrease in growth and difficulty in standing and walking (Worell, 2018; Samour, 2016).

The diagnosis of this disorder can be based on clinical symptoms in the form of the anatomical shape of the foot X-rays. This condition is often neglected by the owner because it is considered not to have any prospects for recovery. However, various therapies for splayed leg have been reported. Some reports states that the condition of the splayed leg can be improved when the birds are still young by treating both their legs in thev right position. This review evaluates the diagnosis, therapy, and prevention of the occurrence of splayed legs in birds, which can be used as a reference to improve bird welfare (Cynthia *et al.*, 2007).

Materials and Methods

This research is a literature study that takes information from journals and books. With limited publication results found, this review is not limited by the time span, regarding the incidence, diagnosis and therapy of splayed

leg in various birds. The data obtained were analyzed descriptively which was used as the basis for the review.

Results and Discussion

Etiology

The splayed leg can occur due to genetic influences, developmental problems during incubation, improper substrate that does not allow the bird to hold its legs in the right anatomical position, dietary imbalance leading to secondary nutritional hyperparathyroidism with or without pathological fractures, slipping of the tendons and gastrocnemius (Worell, 2018). Papatsiros (2012), succeeded in identifying the gene in the muscle that causes splayed leg, namely the CDKN3 gene. There are two types of splayed legs, the first is the congenital form (acquired before birth) where the bird hatches with an abnormal leg position because the position when it was still inside the egg is already in an abnormal position. These chicks are unlikely to return to normal position without prompt action and can even worsen their condition. The second type of splayed leg is the form due to mismanagement and this one can be prevented through good maintenance and management. This type of splayed leg is due to some factors, the most common cause is the improper diet that does not meet the metabolic needs of the brood stock. Most often associated with low levels of calcium in the diet, but can also be associated with levels of protein and other minerals that are necessary for bone formation (Worell, 2018).

To prepare for the reproductive period of birds, complete feeding long before the breeding season begins is very important, and it is not appropriate to initiate calcium supplementation and complete food when mating birds or when hatchlings hatch. Prepared eggs full of nutrients and energy will increase hatchability. Young birds that are too close together early on are something that is often found in birds with high reproductive rates. Leaving eggs that are not hatched yet in the nest allows the hatchlings to have something to lean on and will also prevent birds from sitting too tightly together, but this is not recommended. The easiest way to prevent chickens from getting splayed legs is

to have a substrate suitable for the type of bird. Most breeders will forget to clean the substrate after the first production. The use of pine wood shavings can be an option and there are some breeders using coconut fiber and similar fibers (Samour, 2016).

Angular limb deformity appears to occur when more weight on one side of the foot grows than the other, resulting in abnormal bone growth in the affected limb. In most cases, rotation involves the tibiotarsus and is diagnosed in rapidly growing baby birds; however, angular deformities are also seen in the femur and tarsometatarsus (Worell, 2018).

Dietary imbalance and some of the causes that cause the legs to widen can also be associated with this condition. Surgical correction by performing a de-rotating osteotomy with the placement of external fixation may be required to correct or attempt to correct the deformity. Defects of angular limbs and widened legs are commonly reported in cockatiels, lovebirds (*Agapornis* spp.), budgies (*Melopsittacus undulatus*), pigeons (*Columba livia*), pigeons, and African gray parrots (Worell, 2018). An

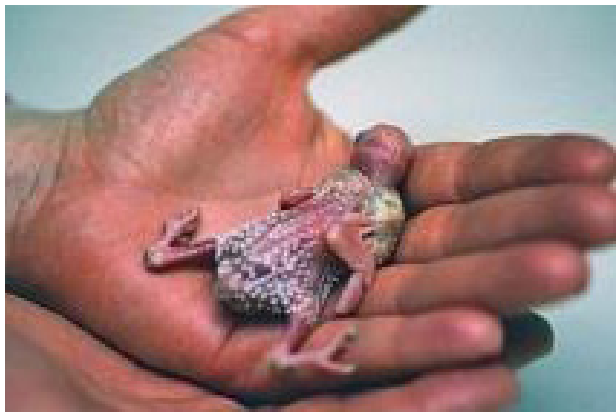

Figure 1. Splay leg in parakeet chicks (*Melopsittacus undulatus*) (Worell, 2018)



Figure 2. Limb deformity in the left leg of the yellow-headed young Amazonian parrot (*Amazona ochrocephala oratrix*) and in love bird [3]

example of a splayed leg due to a slippery bottom problem is presented in Figures 1 and 2. The splayed leg is common in young birds aged one month. This research is a literature study that takes information from journals and books. With limited publication results found, this review is not limited by the time span, regarding the incidence, diagnosis and therapy of splayed leg in various birds. The data obtained were analyzed descriptively which was used as the basis for the review.

Clinical Symptoms, Diagnosis and Prognosis

Splay legs are usually effortless to recognize clinically, namely from abnormal leg formations such as bent legs, legs straddled or legs spread to the side. Symptoms that are often encountered include abnormal walking and an abnormal standing position (Worell, 2018). The diagnosis can be determined based on the first treatment that was given and palpation of anatomical or by X-rays to further clarify the diagnosis. Prognosis in the case of splayed leg depends on the age when treatment was first given, i.e. the sooner we take action, the greater will be as the leg may return to normal position. But the longer the age of the bird that is not immediately treated the less likely it is to recover to a normal position (Worell, 2018).

Therapy

Therapy that can be given in cases of splayed leg depends on the cause. Splayed leg caused by genetics has a poor prognosis so the therapy will not give an improvement impact, but still prevention efforts can be done by providing balanced nutrition, sufficient amounts of calcium and protein for the growth period, and getting



enough sunlight. Splayed leg caused by external factors such as maintenance management error can be treated by giving treatment to return the foot to a normal anatomical position (Worell, 2018; Samour, 2016).

Depending on the severity of the leg deviation and the age at which the bird is brought in for an examination, techniques to treat this condition include making an assistive device to position the bird's leg using an assistive device (Cynthia and Scott, 2007).

The use of other tools in this case can also use a stick and be attached to the chick's legs in a small container where the legs cannot be spreaded to the side (Cynthia and Scott, 2007).

These techniques may or may not be effective in correcting foot deformities. Birds of old age when bones are no longer growing or with severe deformities require surgical treatment. In many of these cases, euthanasia can also be considered because of the poor prognosis and high costs involved in treating these cases with postoperative procedures and care. Angle limb deformity, which is sometimes called rotational leg deformity, is considered a congenital or acquired condition that occurs when the distal



Figure 3. Lovebird chicks with a ribbon to restore their normal position on their feet (Worell, 2018).




Figure 4. Lovebird chicks with sticks to restore normal foot position (Worell, 2018).

limb deviates medially or laterally from its normal anatomic position (Luparell *et al.*, 2016).

In these cases, surgical repair of the damaged soft tissue may be attempted in the larger species and assisted internal fixation is the technique of choice (Bennett, and Owens, 1997; Bowles and Zantop, 2002). In this case the cockatiel bird (*Nymphicus hollandicus*) was 35 days old with a disability condition to stand (Figure 5). The media- cranial deformity of the femoral tibiotarsal joint is seen on radiographs (Figure 5).

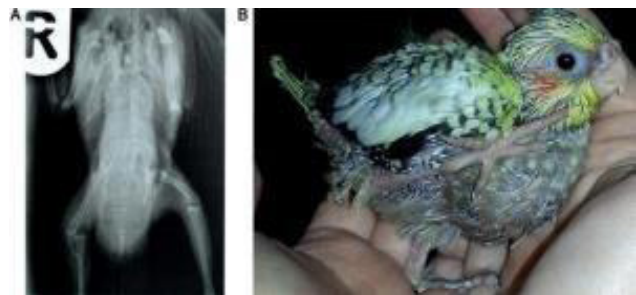


Figure 5. The bird's foot was abnormal before treatment. A) Radiography show rontgen medio-cranial luxation femoro tibialis joint B) External foot of bird (Luparell *et al.*, 2016)

As the young age of the chicks increases the chances of good healing, this problem can be solved by positioning the foot with semi-rigid foam (Figure 6, 7) (Luparell *et al.*, 2016).




Figure 6. Foam used to fix the affected part of the foot. A) Two part of foam are use for foot splint B)Application of foam (Luparell *et al.*, 2016)

After 20 days, birds can stand with a normal foot position with physiotherapy every day, the bird's condition shows good progress, although the ability to walk is not completely normal due to stiff joint ankylosis. The bird also had moderate left pododermatitis which resolved within 2 months with topical therapy. There were no signs of pododermatitis on the right leg despite ankylosis of the stiff joint (Luparell *et al.*, 2016).

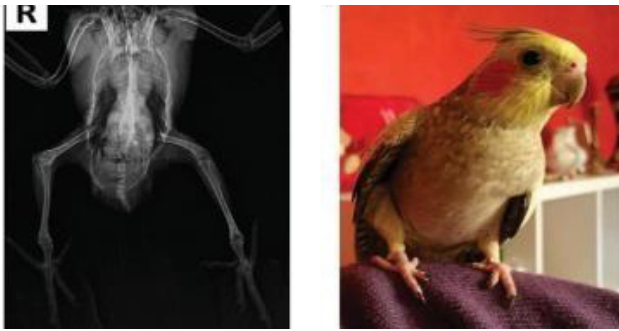

Figure 7. The bird's foot was normal after treatment. A) Radiography show rontgen medio-cranial show normal position on femoro tibialis joint, B) The bird can stand by his self (Luparell *et al.*, 2016)

The use of this semi-rigid foam rubber device is an effective method of maintaining the foot in a normal position, enabling joint stabilization in growing birds belonging to smaller species where surgical repair of ligaments tends to be difficult. Several methods that have been used for the treatment of splayed leg are ribbon method, stick method, foam method, and rubber method (Luparello *et al.*, 2016; Duerr and Gage, 2020).

Advantages and disadvantages

Isolation in splayed leg therapy is quite often applied because the materials are quite easily obtained, the healing rate is quite high and the effects of stress are small. In sticks, it is rarely used because the level of stress caused is quite high because the bird's feet cannot really move because they are maximally fixed. Foam is also rarely used because the material is quite complicated to apply, and the bird's feet are fixed but on a different medium, so it still has a better level of comfort than using sticks. The use of rubber by fixing the middle is often applied to chickens and birds with simple ingredients and with a high success rate; the level of stress caused is also small, so the use of insulation and rubber in splayed leg therapy is more recommended. Therapy that can be given in cases of splayed legs depends on the cause of the condition (González, 2019).

Conclusion

A splayed leg is a condition where it is stretched outwards or sideways from its normal position under the body and often affects young birds. This situation can be overcome by accurate

diagnosis, therapy, and prevention. Therapy is given by using insulating media, sticks, foam, and rubber. Based on the above presentation, using a mid-fixed rubber band is the most recommended therapy to adjust the size of the foot and its needs with a high success rate and a low-stress level.

References

- Bennett, P. M., and Owens, I.P.F. (1997) Variation in extinction risk among birds: chance or evolutionary predisposition. *Proceedings of the Royal Society of London. Series B: Biological Sciences* 264.1380. 401-408.
- Bowles, H.L., and Donald W. Z. (2002) A novel surgical technique for luxation repair of the femorotibial joint in a monk parakeet (*Myiopsitta monachus*). *J. of Avian Medicine and Surgery*. 16(1): 34-38.
- Cynthia, K., Scott, L. (2007) *The Merck/Merial manual for pet health*. Whitehouse station, NJ, Merck&Co. 838 – 839.
- Duerr, R.S., and Gage, L. J. (2020) *Hand-Rearing Birds*, 2nd edition. India: Willey Blackwell. 144.
- González, M.S. (2019) Avian articular orthopedics. *Veterinary Clinics: Exotic Animal Practice*. 22(2): 239–251.
- Luparello, M., Faraci, L., Giuseppe, M.D., Crosta, L. (2016) Correction of neonatal stifle luxation in a 35-day-old cockatiel (*Nymphicus hollandicus*). *Journal of small animal practice, BSAVA*. 57: 653–654.
- Paspatsiros, V.G. (2012) The Splay Leg Syndrome in Piglets: a review. *American of Animal and Veterinary Science*. 7(2): 80 – 83.
- Samour. (2016) *Avian Medicine*, 3rd edition. Abu Dhabi, Elsevier. 555.
- Setiana, T., Masy'ud, B., Hernowo, J.B. (2018) Faktor Penentu Keberhasilan Teknis Penangkaran kakaktua kecil jambul kuning (*cacatua sulphurea sulphurea*). *Media Konservasi*. 23(2): 132–139.
- Worell, A.B. (2015) Current trends in avian pediatrics. *Journal of Exotic Pet Medicine*. 21(2): 115-123.