

RESEARCH ARTICLES

The Effectiveness of injectable platelet-rich fibrin and bone graft addition to open flap debridement for infrabony pocket therapy

Rizka Dindarini*, Dahlia Herawati**, Sri Pramestri Lastianny**✉

*Periodontics Specialty Program, Faculty of Dentistry, Universitas Gadjah Mada, Yogyakarta, Indonesia

**Department of Periodontics, Faculty of Dentistry, Universitas Gadjah Mada, Yogyakarta, Indonesia

**Jl Denta No 1 Sekip Utara, Yogyakarta, Indonesia; ✉ correspondence: sri.pramestri@ugm.ac.id

ABSTRACT

Various biomaterials have been utilized as additional material to help tissue regeneration in the open flap debridement (OFD) procedure. Platelet-rich fibrin (PRF) is an autologous platelet concentrate that contains many growth factors (GFs) and generally used as an additional biomaterial in OFD. However, PRF has several weaknesses, such as its consistency, which is hard to mix with another biomaterial, and its abundant sediment of regenerative cells resulted from high-speed centrifugation. Injectable Platelet Rich Fibrin (I-PRF) is one of the PRF derivatives that contain more regenerative cells. Due to the low-speed centrifugation, I-PRF has a liquid form. Certain GFs were also found in I-PRF, such as PDGF, TGF- β 1, VEGF, IGF, EGF dan COL-1a. In this study, we measured probing depth (PD), relative attachment level (RAL), and bone height as the healing parameter, to see the effectiveness of I-PRF addition and bone graft in the OFD for infrabony pocket as the aim of this study. Twenty (20) periodontal pockets were chosen (PD= 5-7 mm) and divided into OFD+I-PRF+bone graft (bg) group (group I) and OFD+PRF+bg group (group II) equally. The clinical evaluation was measured at the baseline, day-30, and day-90. Results showed that PD ($p= 0.022$) and RAL ($p= 0.008$) significantly increased in group I (PD 2.80 ± 0.42 ; RAL 2.50 ± 0.52) compared to group II (PD 2.10 ± 0.73 ; RAL 2.00 ± 0.67); however, there was no significant difference in the bone height ($p= 0.194$). Taken together, our data revealed that I-PRF+bg induces soft tissue regeneration in infrabony pocket treatment.

Keywords: bone graft; I-PRF; infrabony pocket; open flap debridement; PRF

INTRODUCTION

It has been widely known that periodontal therapy aims to regenerate damaged periodontal tissue, including periodontal ligament function, alveolar bone, and cementum.¹ Scaling and root planning (SRP) and open flap debridement (OFD) surgery are the treatment of choice to eliminate pockets and repair periodontal tissue.² Infrabony pocket is one feature of periodontal tissue damage, characterized by the higher appearance of apical pocket basal compared to the adjacent alveolar bone and the presence of vertical bone damage. The clinical features of infrabony pocket itself can be found through probing depth and clinical attachment level evaluation and X-ray imaging to see the patterns of bone damage.³ Infrabony pocket repair in periodontal tissue requires surgery,¹ specifically with the size of more than 5 mm deep after the initial phase or after therapy.⁴

The use of biomaterials, such as root conditioning agent, growth factors (GFs), guided tissue regeneration (GTR), and bone graft materials, as an adjunct in OFD treatment, has shown to give preferable results on periodontal tissue regeneration compared to the OFD treatment only.^{1,2} Ideally, biomaterials used in periodontal tissue regeneration are supposed to be biocompatible, safe, non-allergenic, non-toxic, and free from disease carrier. These biomaterials should be strong enough to maintain the healing space and preserve a reasonable degradation rate.² The autograft bone graft is the gold standard for network regeneration. However, it is no longer used due to its limitation on the usable area. The alloplastic bone graft has become an alternative since it is easy to obtain, biocompatible, and has osteoconductive abilities. Clinically, a bone graft is used to keep soft tissue from invading the injured area, stabilize the blood clot, and facilitate bone

formation. Alloplast bone graft is considered useful in osteoconductive properties only. Therefore, distinct biomaterial addition is necessary to help bone tissue regeneration.⁵

Platelet concentrate has been widely used in dentistry for more than three decades as a regenerative material known to release many GFs to trigger tissue regeneration and is considered an autologous source.⁶ Platelet-rich fibrin (PRF) is a second-generation autologous platelet concentrate found to form a three-dimensional fibrin matrix. This concentrate is useful as a framework for tissue regeneration due to its capability to grow into a membrane in both guided bone regeneration (GBR) and guided tissue regeneration (GTR) procedures and release various GFs in the network repair process.⁷

Despite its wide application, PRF has several drawbacks, such as the low amount of protein concentration, which is hard to mix with another biomaterial. High-speed centrifugation (2700 rpm) in the PRF preparation process generates abundant sediment of GFs-containing cells such as platelets and leukocytes.⁶ Therefore, platelet concentrate was re-developed to create a PRF liquid form called injectable platelet-rich fibrin (I-PRF).⁸

Preparation of I-PRF was carried out using a lower centrifugation speed (700 rpm) and time, resulting in a higher content of regenerative cells and a higher GFs concentration than PRF.⁹ Choukroun and Ghanaati (2018) stated that centrifugation rate reduction, in the autologous platelet preparation, from the highest to the lowest, indicates a higher number of GFs (VEGF and TGF- β 1) concentrates and an increase in the number of platelets and leukocytes that play an essential role in the wound healing process. According to Varela et al. (2018), the liquid form of this autologous platelet I-PRF concentrate provides benefits for clinicians because it can be used in periodontal tissue regeneration with or without the addition of other biomaterials. However, the effectiveness of I-PRF addition and bone graft in OFD for infrabony pocket treatment remains elusive. The effectiveness of I-PRF

compared to the normal PRF and bone graft is still unknown as well. This study demonstrated the effectiveness of I-PRF addition and bone graft in OFD for infrabony pocket treatment by measuring several parameters such as probing depth, relative attachment level, and bone height.

MATERIALS AND METHODS

This study has been approved by the Ethics Committee of Dentistry, Universitas Gadjah Mada (No. 00294/KKEP/FKG-UGM/EC/2019). The study subjects were taken from patients who visited RSGM UGM Prof. Soedomo and were diagnosed with chronic periodontitis, who fit the inclusion criteria: patients were either male or female, 30-55 years old, non-smoker, with no systemic condition. Patients with surgical history, pregnancy, antibiotics, or any drug history in the last 6-months were excluded from this study.

Infrabony pockets were identified from lower posterior teeth with the following criteria: probing depth of 5-7 mm, with vertical bone destruction, and no furcation involvement. Twenty infrabony pockets were divided into two groups. The first group, or referred to as group I (n = 10), was treated with open flap debridement with I-PRF and bone graft (OFD+I-PRF+bone graft), while the second group, or referred to as group II (n = 10), was treated with open flap debridement with PRF and bone graft (OFD+PRF+bone graft).

Blood samples were taken into two 10 ml tubes and prepared for the blood concentrate preparation. For the I-PRF preparation, the blood was taken with plain plastic (non-anti-coagulant) tubes then centrifuged using DLAB DM 0412 Clinical Centrifuge at 700 rpm (60g) for 3 minutes.^{6,10} The upper liquid layer was taken as I-PRF by using a syringe and then mixed with the bone graft prior to applying it together to the surgical area. For the PRF preparation, the blood was taken with a plain glass tube then centrifuged at 2700 rpm for 12 minutes.⁶ The PRF clot layer, which would be in the middle of the tube, was taken with pinset, cut into small pieces with surgical scissors, and then mixed with the bone graft before applying it to the surgical site.

Probing depth (PD) was defined as the distance between the margin of the gingiva to the bottom of the pocket measured with UNC-15 probe applied in parallel to the tooth axial. Relative attachment level (RAL) was defined as the attachment of tooth support tissue measured using a UNC-15 probe inserted into the tooth's axial parallel pocket and recorded from a fixed point determined on the occlusal stent to the base of the pocket. Bone height or the alveolar bone height refers to the measurement between the CEJ and the bone defect base, measured by radiographic beam computed tomography (CBCT). PD, RAL, and bone height measurements were taken immediately before the first treatment (baseline). The following examinations were carried out at day 30 and day 90 for PD and RAL, and at day 90 for bone height. A full mouth SRP and oral hygiene control were conducted at least a week before the surgical procedure.

Statistical analysis was performed using IBM SPSS version 25. Data were presented in mean \pm SD. The Mann Whitney U test was performed in PD and RAL at 30 and 90 days follow up. Independent T-test was performed in bone height parameters after 90 days of follow up. $p < 0.05$ was considered statistically significant

RESULTS

After 30 and 90 days of treatment, there was no dropout patient. There was no sign of deterioration in all patients' tooth sites as well. It showed that both treatments worked well in terms of healing, without producing any pain or discomfort in the patients.

Table 1 showed that there are some increased in the mean \pm SD of PD from both group I and group II at day-30 and day-90. The PD reduction showing the extent of the increased PD described the improvement in tissue. Although

Table 1. Mean \pm Standard Deviation of Probing Depth at each measuring time point (mm)

Time	Group I (n = 10)	Group II (n = 10)
Baseline	5.10 \pm 0.31	5.30 \pm 0.82
Day – 30	3.90 \pm 0.56	3.60 \pm 0.84
Day – 90	2.30 \pm 0.48	3.20 \pm 0.63

Group I: OFD + IPRF + bonegraft; Group II: OFD + PRF + bonegraft

Table 2. Mean \pm Standard Deviation of Relative Attachment Level at each measuring time point (mm)

Time	Group I (n = 10)	Group II (n = 10)
Baseline	10.80 \pm 0.63	13.00 \pm 0.47
Day – 30	9.60 \pm 0.51	11.40 \pm 0.69
Day – 90	8.30 \pm 0.67	11.00 \pm 0.66

Group I : OFD+IPRF+bonegraft; Group II : OFD+PRF+bonegraft

Table 3. Mean \pm Standard Deviation alveolar bone height at each measuring time point (mm)

Time	Group I (n = 10)	Group II (n = 10)
Baseline	3.16 \pm 0.96	4.97 \pm 0.55
Day 90	2.19 \pm 0.74	4.32 \pm 0.69

Group I: OFD+IPRF+bonegraft; Group II: OFD+PRF+bonegraft

Table 4. Reduction measurement of Probing Depth and Relative Attachment Level taken at 3 time points: baseline-30 day, baseline-90 day, day 30-day 90. Bone height measurement was taken at baseline-day 90 time point. All data were presented in Mean ± SD.

	Baseline – day 30		Baseline – day 90		Day 30 – day 90		P
	I	II	I	II	I	II	
PD	1.20 ± 0.42	1.70 ± 0.48	2.80 ± 0.42	2.10 ± 0.73	1.60 ± 0.51	0.40 ± 0.51	*0.022
CAL	1.20 ± 0.42	1.60 ± 0.51	2.50 ± 0.52	2.00 ± 0.67	1.30 ± 0.48	0.40 ± 0.51	*0.008
Bone height	-	-	0.97 ± 0.33	0.65 ± 0.65	-	-	0.194

PD and RAL were significant (p<0.05), bone height was not significant (p>0.05)

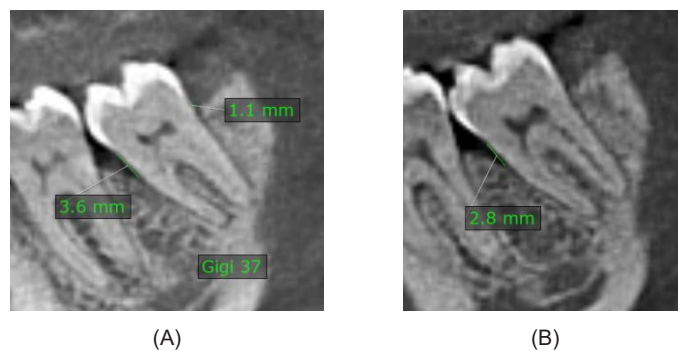


Figure 1. The alveolar bone height measurement before (A) and 90 days (B) after treatment OFD+IPRF+Bonegraft (group I). There are some increases at the mesial tooth 37 = 0.8 mm and at the distal tooth 37 = 1.1 mm

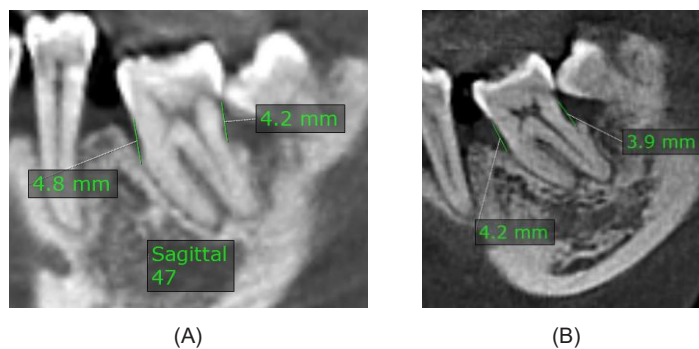


Figure 2. The alveolar bone height measurement before (A) and 90 days (B) after treatment OFD+PRF+Bonegraft (group II). There are some increases at the mesial tooth 47 = 0.6 mm and at the distal tooth 47 = 0.3 mm.

the PD reduction in the baseline-30 day time point showed higher in group II, both baseline-90 day and day 30-day 90 time point showed a higher reduction in group I than group II. The reduction in group I significantly increased at every time point, while in group II there was no increase in the reduction on day 30-day 90, as shown in Table 4.

The same result was also seen in RAL measurement. Table 2 showed there are some

increase in the mean±SD of RAL from both group I and group II at day 30 and day 90. The RAL reduction showing how much the RAL increased, described the improvement in the attachment. In baseline-30 day time point, group II showed a higher reduction. However, in baseline-90 day and day 30-day 90 time point, the group I showed a more significant increase in the reduction than group II. There was a significant increase in RAL

reduction in every time point for the group I, while there was no increase in day 30-day 90 reduction in group II as shown in Table 4.

Table 3 showed that the mean \pm SD of alveolar bone height from group I was higher than that of group II at baseline and day 90. We found an increase in the bone height parameters after day 90, as shown in Table 4. The increase was higher in group I than group II. However, it was not statistically significant.

DISCUSSION

In order to repair periodontal tissue damage, various treatments have been done. These include scaling root planning, surgery (OFD), as well as addition of various biomaterials to help tissue regeneration. In this study, we evaluated the effectiveness of biomaterial addition such as I-PRF and bone graft in OFD for infrabony pocket treatment by measuring several parameters. We found that I-PRF addition in OFD has significantly reduced PD and RAL compared to the PRF. The reduction was significantly higher in every time-point in this group as well. As previously stated, the lower centrifugation speed within PRF-based matrices (I-PRF) the higher its regenerative potential, because it will lead to a higher number of platelet, leukocyte, as well as growth factors as compared to the higher centrifugation speed within PRF-based matrices.⁹

A previous study showed that I-PRF has the ability to slowly release various GFs up to 14 days.¹¹ GFs are known to be involved in the healing process, particularly in the proliferation phase from day-4 to day-21 after the initial injury.¹² Another study showed that I-PRF contains a higher number of platelets compared to PRF and PRP, where platelets have shown to play an essential role in the wound healing process due to their ability to release certain GFs such as Platelet-Derived Growth Factor (PDGF), Transforming Growth Factor (TGF- β), and Insulin-like Growth Factor (IGF). Moreover, other substances such as fibrin, fibronectin, and vitronectin that work as connective tissue matrix and as an effective adhesion molecule

are released by platelets, which is believed to enhance the tissue repairing process.¹³

Although PRF is known to release many GFs and matrix proteins in 7 days, I-PRF-induced proliferation takes more time due to its slower GFs release.¹⁴ Despite the liquid form, I-PRF initiates fibrin polymerization and forms the gel phase macroscopically, explaining the slower release of GFs.⁸ GFs released by platelets could stay longer because of the cellular and acellular components trapped in the fibrin matrix's natural polymerization.¹¹

The reduction of PD and RAL indicates an expected clinical improvement of the periodontal soft tissue due to the new attachment process.¹⁵ This attachment happened due to a new bond between the periodontal ligament fibers to the new cementum and a new attachment between the gingival epithelium to the tooth surface.^{3,15} I-PRF could increase migration, proliferation, and the spread of human fibroblast cells. Besides the high number of platelets, I-PRF also contains many leukocytes, which also play a role in GFs and cytokines expression involved in tissue repair, and act as a defense system against pathogens during the wound healing process.¹⁶

In contrast to PD and RAL results in our study, we could not find any significant difference in the bone height, although there was a higher increasing tendency on day-90 in group I compared to group II. Bone-Morphogenic Protein-2 (BMP2) is a GF that is involved in osteogenesis. BMP2 is found in I-PRF as well. However, its concentration is lower than in the common blood clot.^{10,12} PDGF, on the contrary, is abundantly expressed by I-PRF. Although PDGF receptor-mediated signaling regulates proliferation and migration of mesenchymal stem cells, its activity also reduces the expression of osteogenesis gene markers, such as type I collagen and bone sialoprotein. Therefore, it may inhibit or gives no effect to the osteogenic mesenchymal cell differentiation.¹¹ This finding was further supported by Iozon et al. (2020), who stated that I-PRF did not show spontaneous osteogenic differentiation when tested against osteogenesis genes. The slight increase in bone

height may occur due to the bone graft used in OFD treatment. Carbonate hydroxyapatite (CHA) used in the bone graft has in vivo solubility and low crystallinity. These features increase calcium and phosphate concentration, which is necessary for bone growth. Moreover, a low crystallinity level provides a faster absorption of CHA, thereby facilitating new bone growth.¹⁷ CHA content are then replaced with the bone through osteoblast-osteoclast coupling and serves as an excellent osteoconductive property.¹⁸

CONCLUSION

Based on our data, we showed that I-PRF addition and bone graft in OFD for infrabony pocket treatment showed an effective result as indicated by the PD and RAL reduction. The limitation of this study was that it was only based on the clinical parameters. Further research is needed to evaluate the addition of I-PRF and bone graft in OFD within a more extended time and more clinical or histological parameters.

REFERENCES

1. Ashawan P, Zade R. Comparative evaluation of bioactive glass bone graft material with platelet rich fibrin and bioactive glass bone graft material alone for the treatment of periodontal intrabony defects: a clinical and radiographic study. *Int J Res Med Sci.* 2016; 4(8): 3288–3329. doi: 10.18203/2320-6012.ijrms20162281
2. Shue L, Yufeng Z, Mony U. Biomaterials for periodontal regeneration: a review of ceramics and polymers. *Biomatter.* 2012; 2(4): 271–277. doi: 10.4161/biom.22948
3. Newman MG, H Tahei H, Klokkevold PR, Carranza FA. *Newman and Carranza's Clinical Periodontology.* Elsevier; 2018. 944.
4. Graziani F, Karapetsa D, Mardas N, Leow N, Donos N. Surgical treatment of the residual periodontal pocket. *Periodontol 2000.* 2018; 76(1): 150–163. doi: 10.1111/prd.12156
5. Ausenda F, Rasperini G, Acunzo R, Gorbunkova A, Pagni G. New Perspectives in the use of biomaterials for periodontal regeneration. *Materials (Basel).* 2019; 12(13): 2197. doi: 10.3390/ma12132197
6. Miron R, Fujioka-Kobayashi M, Hernandez M, Kandalam U, Zhang Y, Ghanaati S, Choukroun J. Injectable platelet rich fibrin (i-PRF): opportunities in regenerative dentistry?. *Clin Oral Investig.* 2017; 21(8): 2619–2627. doi: 10.1007/s00784-017-2063-9
7. Panda S, Doraiswamy J, Malaiappan S, Varghese SS, & Del Fabbro M. Additive effect of autologous platelet concentrates in treatment of intrabony defects: a systematic review and meta-analysis. *J Investig Clin Dent.* 2016; 7(1): 13–26. doi: 10.1111/jicd.12117
8. Varela HA, Souza JCM, Nascimento RM, Araújo RF, Vasconcelos RC, Cavalcante RS, Guedes PM, Araújo AA. Injectable platelet rich fibrin: cell content, morphological, and protein characterization. *Clin Oral Investig.* 2019; 23(3): 1309–1318. doi: 10.1007/s00784-018-2555-2
9. Fujioka-Kobayashi M, Miron RJ, Hernandez M, Kandalam U, Zhang Y, Choukroun J. Optimized platelet-rich fibrin with the low-speed concept: growth factor release, biocompatibility, and cellular response. *J Periodontol.* 2017; 88(1): 112–121. doi: 10.1902/jop.2016.160443
10. Thanasrisuebwong P, Kiattavorncharoen S, Surarit R, Phruksaniyom C, Ruangsawasdi N. Red and yellow injectable platelet-rich fibrin demonstrated differential effects on periodontal ligament stem cell proliferation, migration, and osteogenic differentiation. *Int J Mol Sci.* 2020; 21(14): 1–12. doi: 10.3390/ijms21145153
11. Thanasrisuebwong P, Surarit R, Bencharit S, Ruangsawasdi N. Influence of fractionation methods on physical and biological properties of injectable platelet-rich fibrin: an exploratory study. *Int J Mol Sci.* 2019. 20(7): 1657. doi: 10.3390/ijms20071657
12. Sivoilella S, De M, Brunello G, Ricci S, Tadic D, Marinc C, Lops D, Ferroni L, Gardin C,

- Bressan E, Zav B. Delivery systems and role of growth factors for alveolar bone regeneration in dentistry. *Regen Med Tissue Eng*. 2013. doi: 10.5772/55580
13. Karde PA, Sethi KS, Mahale SA, Khedkar SU, Patil AG, Joshi CP. Comparative evaluation of platelet count and antimicrobial efficacy of injectable platelet-rich fibrin with other platelet concentrates: An in vitro study. *J Indian Soc Periodontol*. 2017; 21(2): 97–101. doi: 10.4103/jisp.jisp_201_17
 14. Iozon S, Caracostea GV, Páll E, Şoriţău O, Mănăloiu ID, Bulboacă AE, Lupşu M, Mişu CM, Roman AL. Injectable platelet-rich fibrin influences the behavior of gingival mesenchymal stem cells. *Rom J Morphol Embryol*. 2020; 61(1): 189–198. doi: 10.47162/RJME.61.1.21
 15. Borges CD, Riboldi MS, Messoria MR, Palioto DB, Souza SLS de, Novaes Júnior AB, Taba Jr M. Clinical attachment loss and molecular profile of inflamed sites before treatment. *J Appl Oral Sci*. 2019; doi: 10.1590/1678-7757-2018-0671
 16. Wang X, Zhang Y, Choukroun J, Ghanaati S, Miron RJ. Effects of an injectable platelet-rich fibrin on osteoblast behavior and bone tissue formation in comparison to platelet-rich plasma. *Platelets*. 2018; 29(1): 48–55. doi: 10.1080/09537104.2017.1293807
 17. Saskianti T, Yuliartanti W, Ernawati DS, Prahāsanti C, Suardita K. BMP4 expression following stem cells from human exfoliated deciduous and carbonate apatite transplantation on *rattus norvegicus*. *J Krishna Inst Med Sci Univ*. 2018; 7(2): 56–61.
 18. Jebahi S, Saoudi M, Badraoui R, Rebai T, Oudadesse H, Ellouz Z, Keskes H, El Feki A, El Feki H. Biologic response to carbonated hydroxyapatite associated with orthopedic device: Experimental study in a rabbit model. *Korean J Pathol*. 2012; 46(1): 48–54. doi: 10.4132/KoreanJPathol.2012.46.1.48