

Triple valve replacement on rheumatic heart disease patient: a case report

Haryo Aribowo^{1*}, Yoga Arditya², Yosua Martin²

¹Cardiovascular and Thoracic Surgery Division, Department of Surgery, Dr. Sardjito General Hospital – Faculty of Medicine, Public Health and Nursing Universitas Gadjah Mada, Yogyakarta, Indonesia, ²Cardiovascular and Thoracic Surgery Division, Department of Surgery, Dr. Sardjito General Hospital, Yogyakarta, Indonesia

<https://doi.org/10.22146/inajbcs.v56i4.18258>

ABSTRACT

Submitted: 2023-03-29
Accepted : 2023-08-12

Triple valve replacement surgery is a complex, open-heart surgery to permanently replace all three heart valves (mitral, aorta, and tricuspid) in situations such as valvular diseases as complications of rheumatic heart disease. The expected outcome of the surgery is the proper functioning of the heart valves and the improvement of intracardiac blood flow. Triple valve replacement surgery is still considered a challenging procedure to be performed in developing countries including Indonesia due to its complexity and difficulties. The procedure needs a capable surgeon followed by the prolonged use of cardiopulmonary bypass machines and aortic cross-clamping procedures. This study presented the result of a successful triple valve replacement surgery on a 45 y.o. female with rheumatic heart disease who has manifested into cardiac valve complications. Follow-up examinations conducted directly after surgery, on the 1st, 8th postoperative day, and six months after discharge showed the desired outcome of well-functioning mechanical valves and normal global systolic function of the left ventricle, without significant postoperative cardiac events and complications. The result indicated that triple valve replacement surgery is a safe and effective procedure for rheumatic heart disease patients requiring surgical replacement of all three heart valves, encouraging more implementation of this procedure.

ABSTRACT

Operasi penggantian tiga katup adalah operasi jantung terbuka yang kompleks untuk mengganti ketiga katup jantung secara permanen (mitral, aorta, dan trikuspid) pada kasus seperti penyakit-penyakit katup akibat komplikasi jantung rematik. Hasil yang diharapkan dari operasi ini adalah berfungsinya katup jantung dengan baik dan peningkatan aliran darah intrakardial. Operasi penggantian tiga katup masih dianggap sebagai prosedur yang menantang dilakukan di negara berkembang termasuk Indonesia karena kerumitan dan kesulitannya, termasuk dibutuhkannya ahli bedah yang kompeten, penggunaan mesin *bypass* kardiopulmoner dan prosedur *cross-clamping aorta* dalam waktu lama. Laporan kasus ini mendiskusikan hasil operasi penggantian tiga katup yang berhasil dilakukan pada pasien wanita berusia 45 tahun dengan penyakit jantung rematik yang telah bermanifestasi menjadi komplikasi katup jantung. Evaluasi pasien yang dilakukan langsung pasca operasi, pada hari ke 1, 8 pasca operasi, dan enam bulan setelah pasien keluar dari rumah sakit menunjukkan adanya perbaikan klinis pasien, katup mekanik yang berfungsi dengan baik dan fungsi sistolik ventrikel kiri yang normal, tanpa adanya komplikasi pasca operasi. Hasil tersebut menunjukkan bahwa operasi penggantian tiga katup merupakan prosedur yang aman dan efektif untuk pasien dengan penyakit jantung rematik yang membutuhkan penggantian tiga katup jantung dengan prosedur bedah, sehingga prosedur ini dapat lebih banyak diterapkan di kemudian hari.

Keywords:

developing countries;
rheumatic heart disease;
triple valve replacement;
triple valve surgery;
valvular disease

*corresponding author: haryoaribowo@ugm.ac.id

INTRODUCTION

Acute rheumatic fever (ARF) is a post-infectious sequelae of pharyngeal infection caused by *Streptococcus pyogenes*, or Group A β -hemolytic *Streptococcus* (GABHS). Further damage to the valve tissue within the heart, named rheumatic heart disease (RHD), can become a chronic condition leading to valvular diseases, congestive heart failure, strokes, endocarditis, and death. The case number of RHD keep rising, especially in developing nations, with estimated over 15 million cases of RHD worldwide.¹ Echocardiography as a diagnostic screening tool for RHD in developing nations has led to a marked increasing incidence. Indonesia has a high occurrence of RHD and ranks fourth globally (following China, India, and Pakistan), with an estimated 1.18 million cases annually in 2015.²

Patients with RHD that has significantly affected their heart valves require surgical intervention, either through repair or replacement of the valves. In Indonesia, 59.14% of RHD cases in children and young adults require surgical intervention.³ If the aortic, mitral, and tricuspid valves are all damaged, the procedure to replace all three valves can be conducted simultaneously in a single operation known as triple valve replacement (TVR). Currently, the TVR is a demanding surgical procedure. It presents significant challenges for many cardiac surgeons due to the prolonged utilization of cardiopulmonary bypass (CPB) machines and aortic cross-clamping, particularly when treating patients frequently presenting with advanced stages of RHD.⁴ A historical cohort study revealed that the 30-day mortality rate after TVR surgery, including in-hospital mortality, was 6%, with an all-cause mortality rate of 16%. However, the improvement in patient survival after the TVR procedure could be attributed to factors such as enhanced myocardial protection and

cardiopulmonary bypass techniques, greater experience with the procedure, advancements in treating postoperative heart failure, close patient monitoring, and comprehensive education on anticoagulants.⁵

The triple valve replacement surgery is considered as an uncommon case in the Dr. Sardjito General Hospital, Yogyakarta. Rheumatic heart disease complications to the cardiac valves mostly affect mitral and aortic valves thus only needed a double valve replacement surgery. Addition of tricuspid valve repair is a more common procedure compared to tricuspid valve replacement, therefore making triple valve replacement surgery an uncommon, complicated surgery to be performed. In this study we presented a case of RHD patient in Dr. Sardjito General Hospital, Yogyakarta who successfully underwent TVR surgery without significant postoperative cardiac events and complications.

CASE

Preoperative findings

The patient is a 45 y.o. female with a history of progressive exertional dyspnea. Clinical preoperative data on August 1st, 2022 showed the blood pressure of 146/82 mmHg, heart rate of 76 beats per min (bpm), respiration rate of 24 bpm, temperature of 36.6 °C, and oxygen saturation of 96%. Patient did not report any shortness of breath and chest pain. Physical examination showed stable vital signs with systolic murmur at the second-third intercostal space of the right parasternal line and apical diastolic rumble. Laboratory examination showed normal results. Electrocardiogram revealed right axis deviation and atrial fibrillation with a normal ventricular rate. Chest X-ray showed cardiomegaly and pulmonary edema. transthoracic echocardiography (TTE) showed mitral valve area measured by velocity time integral (MVA VTI) 1 cm²; mitral valve

mean pressure gradient (MV MeanPG) 17 mmHg; aortic valve area measured by VTI (AV VTI) 0.6 cm²; aortic valve MeanPG (AV MeanPG) 63 mmHg; tricuspid valve area measure by VTI (TVA VTI) 0.4 cm²; and tricuspid valve MeanPG (TV MeanPG) 19 mmHg. The result read as severe mitral stenosis, moderate mitral regurgitation, severe aortic stenosis with moderate aortic regurgitation, and severe tricuspid stenosis with severe tricuspid regurgitation. Normal global

and segmental systolic function of the left ventricle (left ventricular ejection fraction/LVEF 74%), and normal systolic function of the right ventricle (TAPSE score 20) were found. The patient can be categorized as a definite case of RHD according to World Heart Federation's Echocardiographic Guideline of Rheumatic Heart Diseases (mitral stenosis with mean gradient greater than or equal to 4 mmHg).⁶

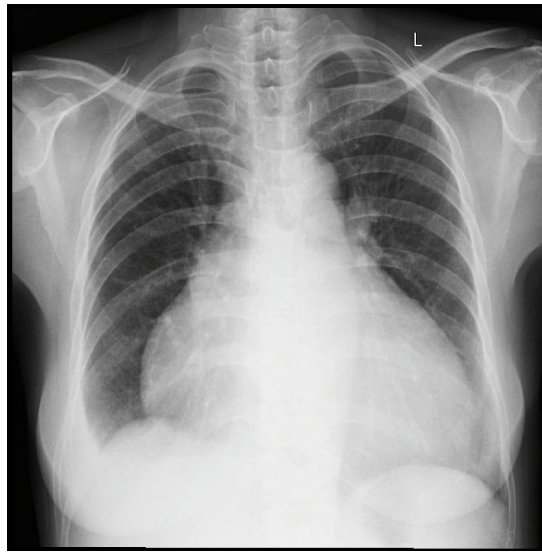


FIGURE 1. Preoperative chest X-ray showing cardiomegaly and pulmonary edema

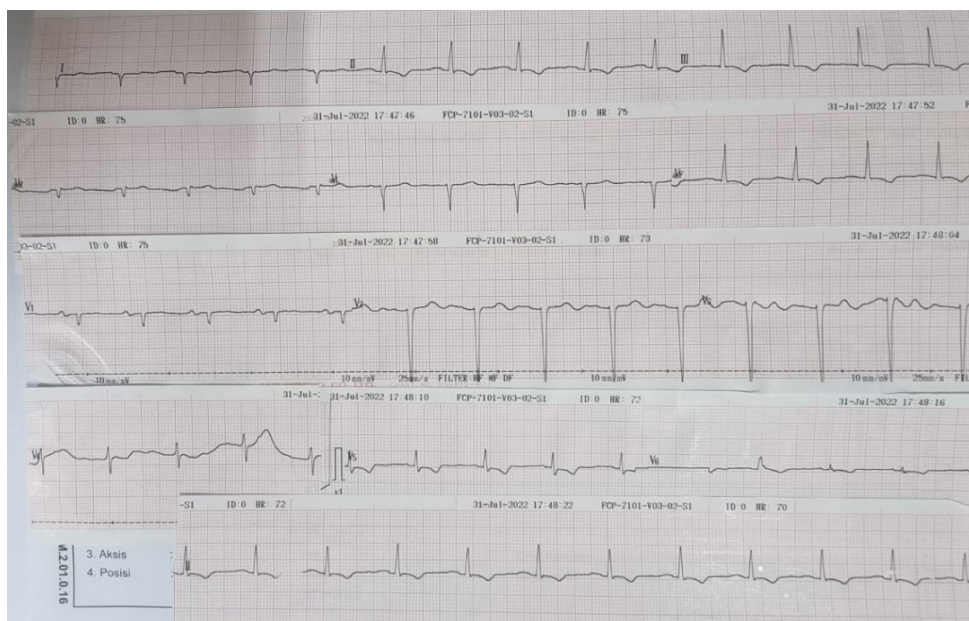


FIGURE 2. Preoperative electrocardiogram showing right axis deviation and atrial fibrillation with a normal ventricular rate

TABLE 1. Preoperative laboratory result

Variables	Unit	Number
Erythrocyte	10 ⁶ /μL	5.44
Leucocyte	10 ³ /μL	7.0
Hemoglobin	g/dL	13.7
Hematocrit	%	42.9
Thrombocyte	10 ³ /μL	116
Albumin	g/L	4.38
SGOT	U/L	41
SGPT	U/L	9.57
HbsAg	-	Non-reactive
INR	-	1.95
PTT	s	11
APTT	s	31.2
BUN	mg/dL	11
Creatinine	mg/dL	0.81
Random blood glucose	mg/dL	118
Sodium	mmol/L	134
Potassium	mmol/L	5.12
Chloride	mmol/L	107

Operative procedure

A median sternotomy approach showed right ventricle enlargement with aorta and superior vena cava dilatation. Cannulations of the aorta, superior vena cava, and inferior vena cava were done followed by the use of a CPB machine and cross-clamping of the aorta. Access to the mitral and aortic valves gained through the right atriotomy showed the calcifications of the anterior and posterior mitral leaflet, fusion of mitral commissures, and fusion of aortic commissures with cusps thickening and narrowing of the orifice (FIGURE 3A and B). The native aortic valve was replaced by the 16 mm mechanical valve with 15 pledget stitches. The native mitral valve was replaced by the 25 mm mechanical valve with 16 pledget stitches. The fusion of the tricuspid leaflets was then found with the thickening of the leaflets. The native tricuspid valve was replaced by the 29 mm mechanical valve with

20 pledget stitches (FIGURE 3C). Cross-clamping of the aorta was released and the CPB machine was weaned. The evaluation of the heart valves was conducted with transesophageal echocardiography (TEE). Decannulations were done followed by the placement of drainage tubes. The total CPB machine time use was 223 min, aortic cross-clamp time was 186 minutes, and ischemic time was 177 min with approximately 1000 mL of total blood loss.

Postoperative findings

Postoperative TEE showed the results of MVA VTI 18.6 cm², MV MeanPG 2.79 mmHg, AVA VTI 67.2 cm², AV MeanPG 35.9 mmHg, TVA VTI 15.8 cm², and TV MeanPG 1.2 mmHg. Well-functioning mitral, aortic, and tricuspid mechanical valves were observed. Normal global and segmental systolic function of the left ventricle (LVEF 76.6%) was found along with systolic dysfunction of the

right ventricle (TAPSE score 11). The patient was admitted to the intensive cardiac care unit (ICCU) with stable hemodynamics without significant postoperative cardiac complications. Clinical data on postoperative day (POD) 1 showed the blood pressure of 140/75 mmHg, heart rate of 67 bpm, respiration rate of 24 bpm, temperature of 36.5 °C, and oxygen saturation of 100%. Patient did not report any shortness of breath and chest pain. Pericardial drain showed 233 mL of serous hemorrhagic product per 24 hr, meanwhile substernal drain showed 7 mL of serous hemorrhagic product per 24 hr. During eight days

in-ward observation, there were no dyspnea, chest pain, cough, and chest pain episodes reported. Follow-up TTE was done in the POD 8 with the result of MVA VTI of 41.7 cm², MV MeanPG 3.5 mmHg, AVA VTI 83.4 cm², AV MeanPG 42.4 mmHg, TVA VTI 34.3 cm², TV MeanPG 2.5 mmHg, and LVEF 62%. Further TTE follow-up was conducted six months after discharge with the MVA VTI of 45.4 cm², MV MeanPG 5.93 mmHg, AVA VTI 72.9 cm², AV MeanPG 24.9 mmHg, TVA VTI 32.1 cm², TV MeanPG 2.81 mmHg, and LVEF 64% indicating the proper function of mechanical valves.

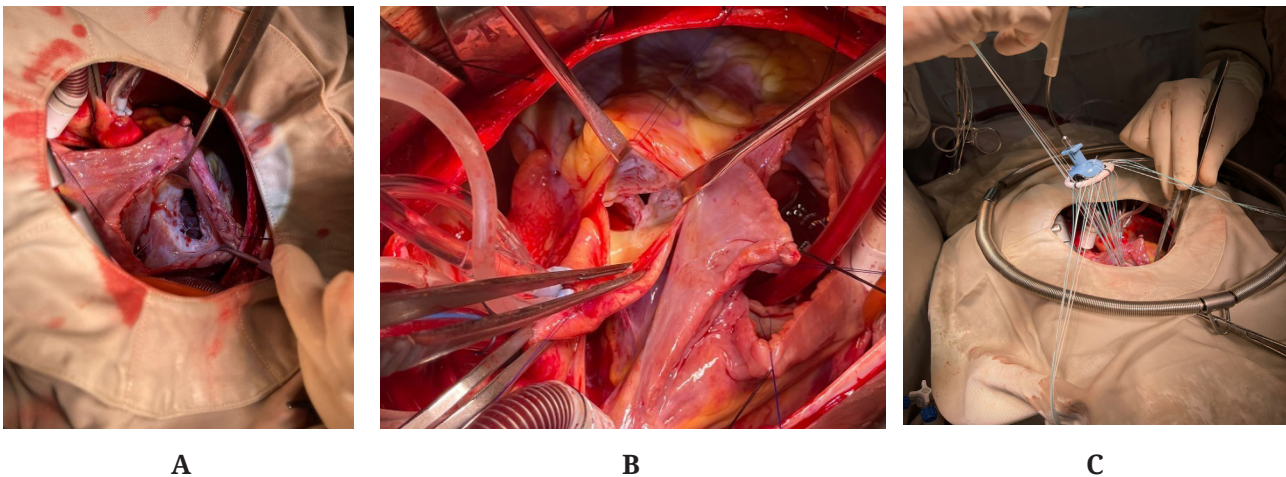


FIGURE 2. Access to the mitral and aortic valves gained through the right atriotomy (A and B); The valves replacement procedure with pledget stitches.

TABLE 2. Preoperative and postoperative transthoracic echocardiography results

Variables	Preoperative	Postoperative	
		8 d follow up	6 d follow up
Mitral			
• MVA VTI (cm ²)	0.92	41.7	45.40
• MV MeanPG (mmHg)	17.00	3.50	5.93
Aorta			
• AVA VTI (cm ²)	0.60	83.40	72.90
• AV MeanPG (mmHg)	63.00	42.40	24.90
Tricuspid			
• TVA VTI (cm ²)	0.40	34.30	32.10
• TV MeanPG (mmHg)	19.00	2.50	2.81

DISCUSSION

In cases of chronic RHD, the mitral valve is commonly affected in approximately 50-60% of cases, followed by a combined lesion involving both the aortic and mitral valves in 20% of cases, and involvement of the tricuspid valve in association with reinfection, mitral, or aortic disease in 10% of cases. The pulmonary valve is rarely affected.⁷ Patients with the involvement of all three cardiac valves have a high risk of mortality. Patients usually fall into NYHA 3 or NYHA 4 functional classification, thus requiring TVR surgery. Triple valve replacement surgery is considered as a challenging procedure to be performed in developing countries including Indonesia due to its complexity and difficulties, such as the need for capable surgeons followed by the high risk due to the prolonged use of cardiopulmonary bypass machines and aortic cross-clamping procedure.

The surgeons need to assess the post-surgery mortality risk. In this study, risk assessment of mortality after cardiac surgery is done with the European system for cardiac operative risk evaluation (EuroSCORE) II. A study by Sembiring *et al.*⁸ conducted in East Java, Indonesia, showed that EuroSCORE II has a good calibration and discrimination for cardiac surgery in Indonesian adults. The case presented in this article have EuroSCORE II result of 1.80%, which shows the predicted mortality of 1-2 among 100 patients in the same condition undergoing the same cardiac surgery. Several studies stated that the most common predictors of high long-term mortality rates are a history of renal failure or peripheral vascular disease, a high NYHA functional score, and low LVEF.^{4,9}

The TVR surgeries in this study were done with a median sternotomy approach followed by cannulations of the great vessels, the use of the cardiopulmonary

bypass machine, the aortic cross-clamping, and the replacement of the native cardiac valves with prosthetic ones in the following order: aortic, mitral, and tricuspid. The systolic dysfunction in the right ventricle discovered through postoperative echocardiography can be attributed to various factors including the utilization of CPB,¹⁰ alterations in right ventricle geometry, intraoperative ischemia, insufficient myocardial protection,¹¹ and external factors such as pericardial damage, modifications in fossa ovale, and the adherence of the right ventricle to the thoracic wall following the surgery.¹² However, postoperative evaluation of physical examination, TEE, and TTE showed alleviation of symptoms and well-functioning mitral, aortic, and tricuspid mechanical valves with no leakage. TEE and TTE remained as the first-line imaging assessment tools for prosthetic heart valves.¹³

The effective use of pledget stitches and interrupted horizontal mattress sutures are thought to contribute to a lower rate of postoperative paravalvular leakage.⁵ Previous study by Gupta in Bangladesh using the similar demographic stats of the patient showed the similar positive result, strengthening the reproducibility claim of the procedure.¹⁴ Another study conducted in Italy by Leone *et al.*,¹⁵ stated that TVR surgery has demonstrated satisfactory results in terms of in-hospital and mid-term mortality rate with renal failure, reoperations, and concomitant coronary artery bypass graft (CABG) as risk factors for mortality. The common differences found in the similar studies are the severity of the valvular diseases and the comorbidities of the patients such as hypothyroidism and pleural effusion. Comorbidities found may affect the preoperative and postoperative care including the use of related drugs, but not the surgical procedures. Ahmed *et al.*¹⁶ presented the increasing use of percutaneous valve replacement

strategies and multiple valvular replacement therapies, including valve-in-valve procedures, may provide clinical improvement of critically ill patients with fewer periprocedural complications.

This finding called for further study to directly compare the efficacy and safety of conventional, surgical procedure to transcatheter procedure in triple valve replacement cases. Due to the patients' lack of compliance to do routine follow-up, we used the 6 mo postoperative data because it was the only clinical and echocardiography data available. Follow-up studies with bigger sample size are needed to confirm the findings, determine mid-term and long-term outcome, and conclude the total survival rate of post TVR surgery patients in our medical center.

CONCLUSION

The triple valve replacement surgery can serve as a safe and effective surgical procedure for rheumatic heart disease patients requiring surgical replacement of all three heart valves. Careful patient selection based on favorable mortality predictors, proper execution of the surgical procedure, and adequate postoperative evaluation are crucial to enhance the chances of success and minimize the complications. This study presented the result of a successful triple valve replacement surgery, thus encouraging the further implementation of this procedure.

ACKNOWLEDGEMENT

The informed consent was obtained from the patient who underwent medical treatment in Dr. Sardjito General Hospital, Yogyakarta. The data used during the study are available on a reasonable request. The authors declare that they have no conflicting interests and funding sources involved in the study.

REFERENCES

1. Seckeler MD, Hoke TR. The worldwide epidemiology of acute rheumatic fever and rheumatic heart disease. *Clin Epidemiol* 2011; 3:67-84. <https://doi.org/10.2147/CLEP.S12977>
2. Watkins DA, Johnson CO, Colquhoun SM, Karthikeyan G, Beaton A, Bukhman G, et al. Global, regional, and national burden of rheumatic heart disease, 1990-2015. *N Engl J Med* 2017; 377(8):713-22. <https://doi.org/10.1056/NEJMoa1603693>
3. Lilyasari O, Prakoso R, Kurniawati Y, Roebiono PS, Rahajoe AU, Sakidjan I, et al. Clinical profile and management of rheumatic heart disease in children and young adults at a tertiary cardiac center in Indonesia. *Front Surg* 2020; 7:47. <https://doi.org/10.3389/fsurg.2020.00047>
4. Shinn SH, Oh SS, Na CY, Lee CH, Lim HG, Kim JH, et al. Short- and Long-Term Results of triple valve surgery: a single center experience. *J Korean Med Sci* 2009; 24(5):818-23. <https://doi.org/10.3346/jkms.2009.24.5.818>
5. Davarpassand T, Hosseinsabet A. Triple valve replacement for rheumatic heart disease: short- and mid-term survival in modern era. *Interact Cardiovasc Thorac Surg* 2015; 20(3):359-64. <https://doi.org/10.1093/icvts/ivu400>
6. Reményi B, Wilson N, Steer A, Ferreira B, Kado J, Kumar K, et al. World Heart Federation criteria for echocardiographic diagnosis of rheumatic heart disease—an evidence-based guideline. *Nat Rev Cardiol* 2012; 9(5):297-309. <https://doi.org/10.1038/nrcardio.2012.7>
7. Dass C, Kanmanthareddy A. Rheumatic heart disease. In: *StatPearls* [Internet]. Treasure Island (FL): StatPearls Publishing; 2023 [cited 2023 Apr 10]. <http://www.ncbi.nlm.nih.gov/books/NBK538286/>
8. Sembiring YE, Ginting A, Puruhito,

- Budiono. Validation of EuroSCORE II to predict mortality in post-cardiac surgery patients in East Java tertiary hospital. *Med J Indones* 2021; 30(1):54-9.
<https://doi.org/10.13181/mji.oa.204536>
9. Alsoufi B, Rao V, Borger MA, Maganti M, Armstrong S, Feindel CM, *et al*. Short- and long-term results of triple valve surgery in the modern era. *Ann Thorac Surg* 2006; 81(6):2172-7; discussion 2177-8.
<https://doi.org/10.1016/j.athoracsur.2006.01.072>
 10. Forsberg LM, Tamás É, Vánky F, Nielsen NE, Engvall J, Nylander E. Left and right ventricular function in aortic stenosis patients 8 weeks post-transcatheter aortic valve implantation or surgical aortic valve replacement. *Eur J Echocardiogr* 2011; 12(8):603-11.
<https://doi.org/10.1093/ejechocard/jeq085>
 11. Jasinski M, Kadziola Z, Bachowski R, Domaradzki W, Wenzel-Jasinska I, Piekarski M, *et al*. Comparison of retrograde versus antegrade cold blood cardioplegia: randomized trial in elective coronary artery bypass patients. *Eur J Cardiothorac Surg* 1997; 12(4):620-6.
[https://doi.org/10.1016/s1010-7940\(97\)00213-3](https://doi.org/10.1016/s1010-7940(97)00213-3)
 12. Zanobini M, Saccocci M, Tamborini G, Veglia F, Di Minno A, Poggio P, *et al*. Postoperative echocardiographic reduction of right ventricular function: is pericardial opening modality the main culprit? *Biomed Res Int* 2017; 2017:4808757.
<https://doi.org/10.1155/2017/4808757>
 13. Lancellotti P, Pibarot P, Chambers J, Edvardsen T, Delgado V, Dulgheru R, *et al*. Recommendations for the imaging assessment of prosthetic heart valves: a report from the European Association of Cardiovascular Imaging endorsed by the Chinese Society of Echocardiography, the Inter-American Society of Echocardiography, and the Brazilian Department of Cardiovascular Imaging. *Eur Heart J Cardiovasc Imaging* 2016; 17(6):589-90.
<https://doi.org/10.1093/ehjci/jew025>
 14. Gupta S, Chowdhury D, Biswas P. Triple valve replacement: a case report. *JNHFB* 2019; 8:42-4.
 15. Leone A, Fortuna D, Gabbieri D, Nicolini F, Contini GA, Pignini F, *et al*. Triple valve surgery: results from a multicenter experience. *J Cardiovasc Med (Hagerstown)* 2018; 19(7):382-8.
<https://doi.org/10.2459/JCM.0000000000000665>
 16. Ahmed T, Shkullaku M, Chahal D, Dawood M, Gupta A. Triple valve replacement in a patient with severe combined aortic and mitral stenosis. *Cureus* 202; 12(3):e7412
<https://doi.org/0.7759/cureus.7412>