

## Papillary thyroid carcinoma post total thyroidectomy: a case report

Darwito<sup>1\*</sup>, Douglas Rama Bayu Ardha<sup>2</sup>, Ika Puspita Sari<sup>1,3</sup>, Firda Ridhayani<sup>3</sup>

<sup>1</sup>Academic Hospital Universitas Gadjah Mada, Yogyakarta, Indonesia, <sup>2</sup>Faculty of Medicine, Diponegoro University, Semarang, Indonesia, <sup>3</sup>Faculty of Pharmacy, Universitas Gadjah Mada, Yogyakarta, Indonesia

<https://doi.org/10.22146/ijpther.6980>

### ABSTRACT

Submitted: 15-02-2023  
Accepted : 27-05-2023

#### Keywords:

FNAB;  
PTC;  
RAI;  
recurrence;  
total thyroidectomy

Thyroid malignancies are considered rare but it is the most common type of endocrine malignancy that increase rapidly over the past decades. Specifically, papillary thyroid carcinoma (PTC) in the pyramidal lobe is extremely rare. Herein, we described a case of recurrence case of PTC in the pyramidal lobe post total thyroidectomy with category VI T2N1M1 (Bethesda classification) with right neck lymph nodes metastasis at once and attempt to determine both clinical presentation and therapeutical strategies to overcome this case to diminish the possibility of tumor recurrence and optimize therapeutic outcomes for PTC recurrence. It was reported a 28 yo female with a diagnosis of PTC from the pyramidal lobe post-total thyroidectomy procedure. A definite diagnosis of PTC is important to understand the patient's condition and as a consideration to decide the appropriate procedure to cure it. The management of PTC with total thyroidectomy followed by removing the possible root source of recurrent PTC, such as the pyramidal lobe, is mandatory to minimize the residual thyroid tissue that dan influenced PTC recurrent. Even though almost all PTC has an excellent prognosis, periodic follow-up after surgery, and patients' adherence to their medication are still required.

### ABSTRAK

Keganasan tiroid dianggap jarang terjadi namun merupakan jenis keganasan yang paling umum terjadi yang mneingkat pesat selama beberapa decade terakhir. Secara khusus *pappilry thyroid carcinoma* (PTC) di lobus piramida sangat jarang terjadi. Pada artikel ini, kami menggambarkan kasus kekambuhan PTC di lobus pyramidal setelah tindakan tiroidektomi total dengan kategori VI T2N1M1 (klasifikasi Bethesda) dengan metastasis kelenjar getah bening yang berlokasi di leher kanan, sekaligus mencoba untuk menentukan presentasi klinis dan strategi terapi untuk mengatasinya. Pembahasan kasus ini bertujuan untuk mengurangi kemungkinan kekambuhan tumor dan mengoptimalkan hasil terapi untuk kekambuhan PTC. Telah dilaporkan seorang wanita berusia 28 tahun dengan diagnosis paska tiroidektomi total. Diagnosis PTC yang pasti penting untuk memahami kondisi pasien dan sebagai pertimbangan untuk menentukan prosedur yang tepat untuk menyembuhkannya. Penatalaksanaan PTC dengan tiroidektomi total yang diharapkan dapat membuang kemungkinan sumber residif PTC, seperti lobus piramidal, wajib dilakukan untuk meminimalkan sisa jaringan tiroid yang dapat mempengaruhi PTC berulang. Meskipun hampir semua PTC memiliki prognosis yang sangat baik, tindak lanjut berkala setelah operasi, dan kepatuhan pasien terhadap pengobatannya tetap diperlukan.

\*corresponding author: darwito@ugm.ac.id

[Copyright © 2023 THE AUTHOR(S). This article is distributed under a <https://creativecommons.org/licenses/by/4.0/>]

## **INTRODUCTION**

Thyroid malignancies are considered rare, accounting for about 0.85 and 2.5% of all malignancies in men and women.<sup>1</sup> However, thyroid malignancy is the most common type of endocrine malignancy that increase rapidly over the past four decades.<sup>2</sup> Most malignant thyroid tumors are epithelial tumors that come from thyroid follicular cells. This malignant tumor develops into four pathological types namely papillary thyroid carcinoma (PTC), follicular thyroid carcinoma (FTC), medullary thyroid carcinoma (MTC), and anaplastic thyroid carcinoma (ATC).<sup>3</sup> The incidence of PTC accounting for 70 – 80% of all thyroid gland malignancy with papillary growth patterns cell, commonly happen.<sup>4</sup>

Papillary thyroid carcinoma is an epithelial malignancy with a differentiated follicular cell.<sup>5</sup> This case presents with a thyroid nodule or forms a mass in the neck.<sup>6</sup> Specifically, PTC in the pyramidal lobe is extremely rare.<sup>7</sup> Fortunately, PTC is popular for its low malignant potential, less aggressive, and good prognosis.<sup>8</sup> Patients under 45 yo, even with neck lymph nodes spreading presentation, have around a 97% ten years survival rate.<sup>9</sup> Even though up to 20% of patients develop locoregional recurrences that needs further treatment, while approximately 10% develop to distant metastasis.<sup>1</sup> These conditions can be influenced of several factors including gender, age, histology, and clinical presentation. In order to accomplish and maintain high survival rates its depends to diagnosis accuracy, treatment option, adherence to medication, and intense long-term follow up.<sup>10</sup>

One of the standard treatments commonly performed for patients with PTC is total thyroidectomy with postoperative radioactive iodine-131 (RAI) adjuvant.<sup>11</sup> Total thyroidectomy is consider due to a low recurrence rate of around 8% after two decades of initial surgery.<sup>12</sup> In this condition, the most

relevant issue is the risk of recurrence near post-total thyroidectomy. Recurrence of PTC after total thyroidectomy with post-RAI adjuvant requires a fully understanding of the disease, especially as it has changed in the last decade. Therefore, identifying clinical presentations and diagnosis management associated with tumor recurrence in a patient with PTC may be helpful to determine appropriate therapeutic strategies. Herein, we describe a case of recurrence PTC in the pyramidal lobe post total thyroidectomy with category VI T2N1M1 (Bethesda classification) with right neck lymph nodes metastasis and at once attempt to determine both clinical presentation and therapeutical strategies to overcome this case to diminish the possibility of tumor recurrence and optimize therapeutic outcomes for PTC recurrence.

## **CASE**

We described the case of a 28-years old female who came to the Surgical Oncology Clinic at Dr. Kariadi Hospital, Semarang on November 7, 2022, with a routine postoperative visit of thyroid cancer removal and then came with the main complaint of being easily tired that accompanied by others complaints of constipation, cold sensitivity, and weight gain. The patient regularly consumes 100 µg of levothyroxine. On physical examination: weight 55 kg, height 155 cm, heart rate 78/min, respiratory rate 20/min, blood pressure 130/80 mmHg, with VAS 1 pain scale, absence of palpebral conjunctiva pallor and scleral icterus. The front side of the neck reports a surgery scar. Palpation reveals a solid mass 2x1 cm in size, a nodular, soft, mobile, without lymph gland enlargement, and painless nodule that is found in the center of the trachea located in pyramidal lobe from the imaging evaluation, namely a neck CT scan and ultrasound. The examination also reported the absence of carotid bruit from auscultation.

The patient also complained about the mass presentation in her neck without pain which had already started three years ago and grown progressively, beginning with a marble size and keep growing. In November 2018, the clinician already did thyroid cancer mass removal, specifically a total thyroidectomy. Then, in September 2020 the ultrasound imaging result showed a mass existence in her neck without residual thyroid tissue presentation. The neck ultrasound reported a 0.71 cm x 0.65 cm mass of lymph nodes that present within the right submandibular intraglandular and level IV lymphadenopathy with a 1.69 cm x 1.44 cm right cervical lymph node enlargement. The laboratory on October 13, 2022 reported high TSH level in 13.18 mIU/L, Hb 11.8 g/dL, leucocyte  $8.2 \times 10^3/\mu\text{L}$ , calcium 2.26 mg/dL, and high thyroglobulin level 490 ng/mL (22 March 2021), completed with the histopathological assessment that present bilateral PTC. The examination reports a diagnosis of malignant, PTC, BETHESDA VI, thyroid malignancy T2N1M1, post total thyroidectomy in November 2018 and 100 mci of RAI in September 2021.

The doctor was diagnosed the patient with recurrence of PTC in

pyramidal lobe after total thyroidectomy and RAI that equipped with lymph node metastasis. The patient was given 100  $\mu\text{g}$  of levothyroxine once daily, vitamin D once time for 24 h, and a third time daily of calcium carbonate. Further evaluation of the general and clinical condition was given. In addition, monthly follow up also suggested to ensure good clinical outcomes with the euthyroid condition before deciding the further treatment.

This study was followed an ethical consideration from the Medical and Health Research Ethics Committee, Faculty of Medicine, Public Health and Nursing, Universitas Gadjah Mada/Dr. Sardjito General Hospital, Yogyakarta with approval number KE/FK/0816/EC/2023.

## DISCUSSION

Thyroid malignancy has unclear etiology but is can triggered by each risk factor including a history of radiation exposure during childhood, especially under five years old, obesity, iodine deficiency, and genetics. Based on anamnesis and physical examination, Shah summarizes the diagnosis and management of thyroid masses in the algorithm as showed in FIGURE 1.<sup>13</sup>

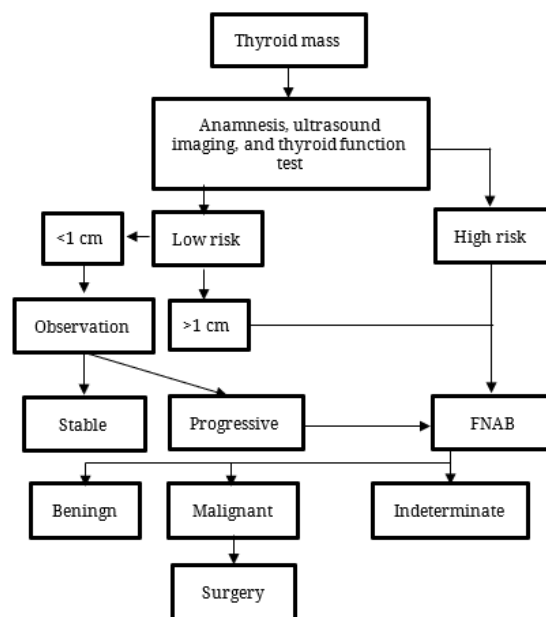


FIGURE 1. The algorithm of thyroid mass management and diagnosis

The diagnosis of a malignant thyroid tumor also can be made based on radiological examinations such as ultrasound, CTscan and histopathological examination. Macroscopically, PTC is usually characterized by a solid form with white-gray colorization, varying size, infiltrative edges, encapsulated, and calcification presentation.<sup>14</sup> In addition, PTC has a papillary structure with oval and fibrovascular nucleus with ground-glass nuclear feature.<sup>15</sup> The appearance of PTC located in the primary lobe was rare but palpation followed by FNA could be used to quickly diagnose the lesion. Therefore, some differential diagnoses should be considered at this time because of the same origin both of thyroglossal duct cyst and pyramidal lobe with same anatomical location. Further assessment, such as neck CT scan, radionuclide imaging, and fine needle aspiration biopsy (FNAB), is important to avoid misdiagnosis between PTC from primary lobe and thyroglossal duct cyst.<sup>16</sup>

Fine Needle Aspiration Biopsy examination has an important role in the evaluation of thyroid nodules that can provide a definite diagnosis.<sup>13</sup> The FNAB examination showed results in accordance with PTC in this case. If the results of the FNAB examination reveal a benign or dubious mass, then a routine ultrasound examination is needed which is carried out at certain intervals based on clinical examination for further monitoring. After the FNAB examination, it should ideally be reported in six categories referred to in the Bethesda System, namely: the non-diagnostic (unsatisfactory) category with a 1-4% risk of malignancy, benign with a 0-3% risk of malignancy, atypia of undetermined significance (AUS) with a risk of malignancy 5-15%, Follicular neoplasm or suspicious (FLUS) with a 15-30% risk of malignancy, suspicious malignancy with a 60-75% risk of malignancy and malignancy with a 97-99% risk of malignancy. The use of the Bethesda System is that it can be used as a guide for the next diagnostic steps

and treatment planning for malignant thyroid tumors.<sup>17</sup>

The effective treatment of symptomatic thyroid neoplasms and thyroid nodules is surgery and RAI as adjuvant therapy. Several approaches that can be done in the operation of thyroid malignancy are total thyroidectomy that will remove whole of thyroid gland. Current guidelines recommend total thyroidectomy for PTC with tumor size more than 1 cm.<sup>18</sup> Based on several evidences, total thyroidectomy is an effective and safe procedure for PTC compare with subtotal thyroidectomy that more potential influence significant recurrence rate and may leave a remaining traces of inadequate treated thyroid mass. Total thyroidectomy followed by an adjuvant of RAI achieves excellent prognosis up to 98-99% 10-years survival rate and around 3% of recurrence rate in low risk well-differentiated thyroid cancer.<sup>11,19</sup> The recurrence risk broadly take into account patient factor, cancer cell characteristics, selected initial therapy, and clinical condition.<sup>111</sup> For this reason, some guidelines states that it is necessary to control thyroid ultrasound examinations and it is recommended every 6-12 months postoperatively and every year thereafter for the first 4-5 years. differentiated thyroid carcinoma with thyroidectomy with or without radiation, then it can only be declared disease-free-stage.<sup>20</sup>

In the present case, the patient had a history of total thyroidectomy in November 2018 and RAI in September 2020, however she was still developed PTC recurrent from the pyramidal lobe due to the residual after the surgery and radiation. The solid mass reappeared and enlarged in the midline of upper neck without the lymph node enlargement. After the total thyroidectomy, approximately 50% of patients reported having residual thyroid tissue; the risk of undetected PTCs in the exact same region was around 4%.<sup>7</sup> Despite the high occurrence of PTC

multifocality, complete surgical removal of the PL must be performed in patients with PTC. In addition, if the PL is not completely removed during the suggested total thyroidectomy, the function of the residual PL will be activated. The PL is considered a potential site for recurrent PTC due to both of the aforementioned reasons. The recurrence of PTC from the pyramidal lobe is mainly brought about by the irregular procedure, while PTC emerging through the PL is quite rare. Reoperation is the first choice if it is possible once the diagnosis of recurrent PTC of the PL has been confirmed.<sup>7,16</sup> The complete removal of the pyramidal lobe using a standardized surgical technique is mandatory in indicated thyroidectomy to remove the possible root source of recurrent PTC.

In this case, the patient regularly consumes 100 µg of levothyroxine after total thyroidectomy and gets the same prescription after the recent diagnosis before doing further surgery because of the high value of TSH laboratory result. Levothyroxine has an important role to restore euthyroidism after total thyroidectomy.<sup>21</sup> Levothyroxine supplementation is also considered to diminish the recurrence of PTC by maintaining the TSH at a normal level.<sup>22</sup> Furthermore, total thyroidectomy can lead to some complications that can occur temporarily and permanently. The complication including postoperative bleeding, infection, dysphonia (neuropathy of the recurrent laryngeal nerve or superior branch of the laryngeal nerve), hypocalcemia (due to trauma to the parathyroid glands) and hypoparathyroidism. Post-thyroidectomy bleeding occurs in 0.36 - 4.3% and shows clinical symptoms such as shortness of breath, ecchymosis, swelling of the neck and dysphagia.<sup>18,23</sup> Postoperative hypocalcemia is the most common complication associated with total thyroidectomy with an incidence ranging from 5-15% due to hypoparathyroidism. Hypoparathyroidism occurs due to

parathyroid gland devascularization, removal or due to hematoma formation causing dysfunction.<sup>24</sup> Hypocalcemia can cause tetany that occurs 12 h postoperatively. Routine post-resection calcium and vitamin D supplementation can prevent hypocalcemic crises and accelerate patient discharge. Roh et al. study recommended 3 g of oral calcium and 1 µg of vitamin D for two weeks starting on the night of surgery.<sup>24</sup> Consume phosphate binders, such as calcium carbonate, could be influenced by a hypothyroidism condition especially in patients with history of total thyroidectomy, an intense evaluation is needed.<sup>25</sup>

## CONCLUSION

Fine needle aspiration biopsy is suggested as a main diagnostic technique to approach a definite diagnosis of PTC specifically to provide a diagnosis of PTC in the pyramidal lobe. The management of PTC with total thyroidectomy followed by removing the possible root source of recurrent PTC, such as the pyramidal lobe, is mandatory to minimize the residual thyroid tissue that can influence PTC recurrence.

## ACKNOWLEDGEMENTS

This work was facilitated by the Dr. Kariadi General Hospital, Semarang, Indonesia.

## REFERENCES

1. Hadmoko ST, Nirmawati K, Pranoto A. Recurrent Papillary Thyroid Carcinoma Posttotal Thyroidectomy With Lung And Neck Lymph Node Metastases. *Journal of Health and Translational Medicine (JUMMEC)*. 2023 Feb 27; 26(1):76-81. <https://doi.org/10.22452/jummec.vol26no1.12>
2. Rossi ED, Pantanowitz L, Hornick JL. A worldwide journey of thyroid cancer incidence centred on

- tumour histology. *Lancet Diabetes Endocrinol* 2021; 9(4):193-4.  
[https://doi.org/10.1016/S2213-8587\(21\)00049-8](https://doi.org/10.1016/S2213-8587(21)00049-8)
3. Negura I, Ianole V, Danciu M, Preda C, Iosep DG, Dănilă R, *et al.* Thyroid Collision Tumors: The Presence of the Medullary Thyroid Carcinoma Component Negatively Influences the Prognosis. *Diagnostics* 2023; 13(2):285.  
<https://doi.org/10.3390/diagnostics13020285>
  4. Kitahara CM, Sosa JA. The changing incidence of thyroid cancer. *Nat Rev Endocrinol* 2016; 12(11):646-53.  
<https://doi.org/10.1038/nrendo.2016.110>
  5. Limaïem F, Rehman A, Anastasopoulou C, Mazzone T. Papillary Thyroid Carcinoma. In: StatPearls [Internet]. Treasure Island (FL): StatPearls Publishing; 2023 [cited 2023 May 25].  
<http://www.ncbi.nlm.nih.gov/books/NBK536943/>
  6. Lloyd RV, Buehler D, Khanafshar E. Papillary thyroid carcinoma variants. *Head Neck Pathol* 2011; 5(1):51-6.  
<https://doi.org/10.1007/s12105-010-0236-9>
  7. Messias H, Sequeira ML, Nogueira R, Zagalo C, Martins M, Gomes P. Pyramidal lobe-dominant papillary thyroid carcinoma—A rare entity with important clinical implications. *Clin Case Rep* 2023; 11(5):e7189.  
<https://doi.org/10.1002/ccr3.7189>
  8. Yu XM, Schneider DF, Levenson G, Chen H, Sippel RS. Follicular variant of papillary thyroid carcinoma is a unique clinical entity: a population-based study of 10,740 cases. *Thyroid* 2013; 23(10):1263-8.  
<https://doi.org/10.1089/thy.2012.0453>
  9. Chen H, Udelsman R. Papillary thyroid carcinoma: justification for total thyroidectomy and management of lymph node metastases. *Surg Oncol Clin N Am* 1998; 7(4):645-63.
  10. Filetti S, Durante C, Hartl D, Leboulleux S, Locati LD, Newbold K, *et al.* Thyroid cancer: ESMO Clinical Practice Guidelines for diagnosis, treatment and follow-up†. *Ann Oncol* 2019; 30(12):1856-83.  
<https://doi.org/10.1093/annonc/mdz400>
  11. Amoako-Tuffour Y, Graham ME, Bullock M, Rigby MH, Trites J, Taylor SM, *et al.* Papillary thyroid cancer recurrence 43 Years following Total Thyroidectomy and radioactive iodine ablation: a case report. *Thyroid Res* 2017; 10:8.  
<https://doi.org/10.1186/s13044-017-0043-4>
  12. Sun JH, Li YR, Chang KH, Liou MJ, Lin SF, Tsai SS, *et al.* Evaluation of recurrence risk in patients with papillary thyroid cancer through tumor-node-metastasis staging: A single-center observational study in Taiwan. *Biomed J* 2022; 45(6):923-30.  
<https://doi.org/10.1016/j.bj.2021.11.009>
  13. Shah JP. Thyroid carcinoma: epidemiology, histology, and diagnosis. *Clin Adv Hematol Oncol* 2015; 13(4 Suppl 4):3–6.
  14. Lukovic J, Petrovic I, Liu Z, Armstrong SM, Brierley JD, Tsang R, *et al.* Oncocytic Papillary Thyroid Carcinoma and Oncocytic Poorly Differentiated Thyroid Carcinoma: Clinical Features, Uptake, and Response to Radioactive Iodine Therapy, and Outcome. *Front Endocrinol* 2021; 12:795184.  
<https://doi.org/10.3389/fendo.2021.795184>
  15. Shin JH. Ultrasonographic imaging of papillary thyroid carcinoma variants. *Ultrasonography* 2017; 36(2):103-10.  
<https://doi.org/10.14366/usg.16048>
  16. Wang M, Zou X, Li Z, Zhu J. Recurrence of papillary thyroid carcinoma from the residual pyramidal lobe: a case report and literature review. *Medicine (Baltimore)* 2019; 98(15):e15210.  
<https://doi.org/10.1097/MD.00000000000015210>
  17. Cibas ES, Ali SZ. The 2017 Bethesda System for Reporting Thyroid Cytopathology. *Thyroid* 2017; 27(11):1341-6.

- <https://doi.org/10.1089/thy.2017.0500>
18. Han L, Li W, Li Y, Wen W, Yao Y, Wang Y. Total thyroidectomy is superior for initial treatment of thyroid cancer. *Asia Pac J Clin Oncol* 2021; 17(5):e170–5.  
<https://doi.org/10.1111/ajco.13379>
  19. Chan S, Karamali K, Kolodziejczyk A, Oikonomou G, Watkinson J, Paleri V, et al. Systematic Review of Recurrence Rate after Hemithyroidectomy for Low-Risk Well-Differentiated Thyroid Cancer. *Eur Thyroid J* 2020; 9(2):73–84.  
<https://doi.org/10.1159/000504961>
  20. Schmidbauer B, Menhart K, Hellwig D, Grosse J. Differentiated Thyroid Cancer-Treatment: State of the Art. *Int J Mol Sci* 2017; 18(6):1292.  
<https://doi.org/10.3390/ijms18061292>
  21. Miccoli P, Materazzi G, Rossi L. Levothyroxine Therapy in Thyroidectomized Patients. *Front Endocrinol (Lausanne)* 2021; 11:626268.  
<https://doi.org/10.3389/fendo.2020.626268>
  22. Ahn D, Lee GJ, Sohn JH, Jeon JH. Oncological impact of hypothyroidism and levothyroxine supplementation following hemithyroidectomy in patients with papillary thyroid carcinoma. *Head Neck* 2020; 42(5):1004-13.  
<https://doi.org/10.1002/hed.26075>
  23. Karakozis S. Management of complications after thyroid surgery. *Hellenic J Surg* 2015; 87(1):115-7.
  24. Bumber B, Potroško V, Vugrinec O, Ferenčaković M, Gršić K. Hypocalcemia After Completion Thyroidectomy for Papillary Thyroid Carcinoma. *Acta Clin Croat* 2020; 59(Suppl 1):136–45.  
<https://doi.org/10.20471/acc.2020.59.s1.18>
  25. Cataldo E, Columbano V, Nielsen L, Gendrot L, Covella B, Piccoli GB. Phosphate binders as a cause of hypothyroidism in dialysis patients: practical indications from a review of the literature. *BMC Nephrol* 2018; 19(1):155.  
<https://doi.org/10.1186/s12882-018-0947-9>